

Perianal Fistulas in Patients With Crohn's Disease, Part 2: Surgical, Endoscopic, and Future Therapies

Stephanie L. Gold, MD, Shirley Cohen-Mekelburg, MD, Yechezkel Schneider, MD, and Adam Steinlauf, MD

Dr Gold is an internal medicine resident in the Department of Medicine at NewYork–Presbyterian/Weill Cornell Medical Center in New York, New York. Dr Cohen-Mekelburg is a gastroenterology fellow in the Department of Gastroenterology and Hepatology at NewYork–Presbyterian/Weill Cornell Medical Center. Dr Schneider is an advanced inflammatory bowel disease fellow in the Department of Gastroenterology and Hepatology at the University of Pennsylvania in Philadelphia, Pennsylvania. Dr Steinlauf is an associate professor of medicine in the Department of Gastroenterology at The Mount Sinai Hospital in New York, New York.

Address correspondence to:
Dr Stephanie L. Gold
1305 York Avenue, 4th Floor
New York, NY 10021
Tel: 917-363-5355
Fax: 212-327-0261
E-mail: slg2005@nyp.org

Keywords

Perianal disease, fistula, Crohn's disease, seton, endorectal advancement flap, stem cell therapy

Abstract: The treatment of perianal fistulas remains a clinical challenge despite the significant advances that have been made in the management of luminal inflammatory bowel disease. In combination with medical therapies, surgical management of perianal fistulas is important for both infection control and definitive repair. Older surgical techniques include the placement of draining and cutting setons and endorectal advancement flaps. Newer surgical techniques that utilize lasers and video-assisted technology are being studied to help patients with chronic, refractory perianal fistulas. In addition to surgical management, less-invasive endoscopic techniques, including endoscopic fistulotomy and endoscopic clipping, are being investigated. Looking forward, allogeneic and autologous adult mesenchymal stem cells are being evaluated to induce fistula healing and improve rates of fistula closure. Here, in the second of a 2-part series on perianal fistulas in patients with Crohn's disease, we discuss the current surgical management of perianal fistulas as well as newer endoscopic techniques and future therapies.

Crohn's disease (CD) is an immune-mediated, chronic inflammatory condition that affects the entire gastrointestinal tract and is often complicated by intestinal strictures and fistulas. Fistulas associated with CD can form between contiguous loops of bowel or an adjacent organ, such as the bladder, urethra, or vagina. Perianal fistulas affect an average of 5% to 40% of patients with CD and are more common in patients who have a higher severity of inflammation of the colon and rectum.¹⁻⁴ Symptoms of perianal fistulas include severe pain, purulent drainage, and fecal incontinence, leading to a significant reduction in quality of life. Successful management of a perianal fistula would ideally result in cessation of drainage and complete healing of the fistulous tract; however, perianal lesions continue to present a significant clinical challenge. The medical therapies that are currently available for the treatment of perianal fistulas in patients with CD were discussed in

the first of our 2-part series.⁵ In conjunction with these therapies, surgical modalities, including the placement of draining setons, can be used to achieve the best clinical outcome. Currently, numerous novel surgical techniques are being studied to less invasively induce fistula healing while maintaining fecal continence. Although various medications and endoscopic and surgical techniques exist, there is no gold-standard treatment strategy for patients with perianal fistulas. However, it is clear that successful management requires a multidisciplinary approach with a gastroenterologist and a colorectal surgeon. Here, in the second of a 2-part series, we discuss the current surgical techniques, novel endoscopic modalities, and future therapies for perianal fistulas in patients with CD.

Surgical Management

Perianal fistula management often requires surgical intervention for both local infection control and definitive treatment of the enterocutaneous tract. There are many options for surgical repair of a perianal fistula, and the choice of which technique is best often depends on the anatomy, presence of local inflammation, type of fistula, and surgeon expertise.

Simple Perianal Fistulas

The preferred surgical intervention for simple perianal fistulas (superficial or low intersphincteric) is an open fistulotomy, given the low risk of fecal incontinence and high rate of complete healing.^{6,7} In the majority of studies evaluating open fistulotomy for superficial fistulas, the healing rate is roughly 80% to 100%.⁷ Fistula recurrence rates are approximately 0% to 20% but can vary.⁷ Incontinence after an open fistulotomy in patients with simple perianal fistulas is rare because the sphincter is not involved. Although healing rates are generally very high and both recurrence and incontinence rates are low, proper patient selection is crucial, and patients with low fistulas without macroscopic evidence of inflammation often have the best results.⁷

Complex Perianal Fistulas

Complex fistulas, involving the internal or external anal sphincter, require a different surgical approach to optimize healing and prevent incontinence. Current guidelines state that local infection control with an incision and drainage and/or seton placement is crucial prior to any definitive medical or surgical management.⁸ Once the perianal infection is controlled, management of the enterocutaneous tract can be planned utilizing techniques such as an endorectal advancement flap, fistula plug or glue, or laser closure.⁸ In complex perianal fistulas, combined surgical and medical management has

been shown to be more effective than either modality alone.⁶ Despite the best therapies for chronic complex perianal fistulas, diverting stomas or even proctectomy may be necessary.²

Draining and Cutting Setons The use of a seton in a patient with a perianal fistula was first described by Hippocrates, who inserted horsehair into an anal tract and periodically tightened it.⁹ Modern draining setons are commonly made of a rubber sling or heavy nylon suture and are frequently used for patients with complex perianal fistulas (Figure). By preventing closure of the external opening and allowing the tract to mature and heal by secondary intention, a seton can be used as a bridge to a complex, definitive surgical repair.⁸ In addition, for patients who have had failed definitive repairs or who do not wish to undergo significant surgical interventions, a draining seton can be used as a long-term remedy, keeping the tract open and preventing abscess formation.⁸ Removal of a draining seton can result in fistula recurrence in approximately 20% to 80% of patients.¹⁰ Although the consensus is to remove the seton once the drainage has completely stopped, the ideal duration of the loose or draining seton remains a clinical challenge. Premature removal of a seton increases the risk of recurrence and new abscess formation, and prolonged seton placement has been associated with poor healing of the fistulous tract.¹¹ In one study, a minimum of 3 weeks of drainage from a loose seton was associated with complex perianal fistula healing¹¹; however, Bouguen and colleagues showed improved healing when seton placement did not exceed 34 weeks.¹² Unlike a draining seton, a cutting seton is placed into a fistula tract and serially tightened, cutting slowly through the sphincter and allowing for healing of the proximal tissue (Figure). Although placement of a cutting seton is minimally invasive, healing is often quite slow, taking an average of 12 to 16 weeks.⁸ Fecal incontinence has been reported in approximately 5% to 10% of patients, limiting the use of a cutting seton in the treatment of complex perianal fistulas.^{8,13}

The use of draining setons in combination with medical therapy, most commonly a biologic agent such as infliximab (Remicade, Janssen), has been shown to increase the rate of fistula closure. In an evaluation of the efficacy of draining setons when combined with infliximab, Regueiro and Mardini found that patients treated with the combination therapy had significantly better healing rates than patients treated with infliximab alone (100% vs 82.9%).¹⁴ Moreover, fistula recurrence rates were reduced with combination therapy (44%) compared with infliximab therapy alone (79%; $P=.001$).¹⁴ Two additional studies documented improved healing

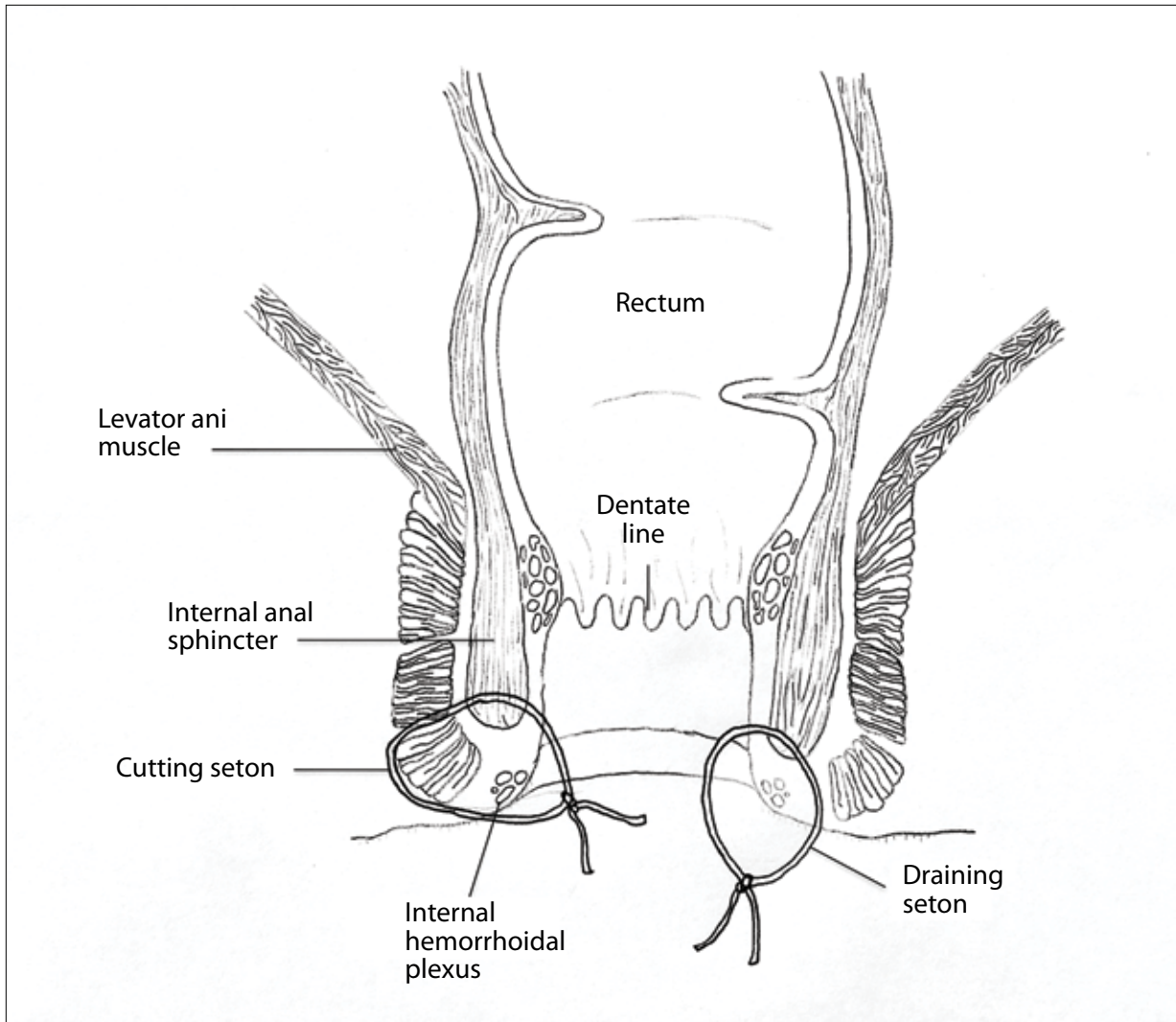


Figure. An illustration of the anal canal with a loose draining seton (right) and a tight cutting seton (left) traversing the internal and external anal sphincters.

with combined infliximab infusion and draining seton placement when compared with monotherapy.^{15,16} There are no studies to date looking at the use of setons in combination with novel biologic agents such as vedolizumab (Entyvio, Takeda) or ustekinumab (Stelara, Janssen).

Endorectal Advancement Flaps Endorectal advancement flaps are the most common surgical technique for the definitive repair of a complex perianal fistula, with success rates ranging from 50% to 80%.¹⁷ This sphincter-sparing procedure involves mobilization of a U-shaped flap of rectal mucosa, submucosa, and muscle fibers to occlude the internal orifice of the fistula tract. Ideally, with no flow through the fistula, complete closure will occur. The majority of research on endorectal advancement flaps

is in patients with fistulas of cryptoglandular origin, and not in patients with perianal CD. Jones and colleagues documented fistula closure after placement of a transanal rectal advancement flap in 58% (11/19) of patients with underlying CD.¹⁸ However, patients with active proctitis were excluded from the study, and 47% (9/19) of patients with CD required a temporary diverting stoma.¹⁸ Most of the studies on endorectal advancement flaps have demonstrated that this procedure is most effective in patients with fistulas of cryptoglandular origin and is less effective in patients with underlying CD.^{17,19} Among patients with fistulizing CD, small bowel involvement and severe active proctitis are associated with lower rates of successful fistula closure after an endorectal advancement flap procedure.^{17,20,21}

Fistula Infill Materials Fibrin glue, a mixture of fibrinogen and calcium, can be injected directly into a perianal fistula, sealing off the tract by forming a thrombin clot.² Initially used in conjunction with other surgical procedures such as an endorectal advancement flap, fibrin glue is now being studied as a monotherapy in patients with perianal CD. Most of the initial studies on fibrin glue were conducted on patients with cryptoglandular perianal fistulas, but studies on patients with CD have shown healing rates in the range of 30% to 80%.^{2,4} In a small study focused on the efficacy of fibrin glue in patients with fistulizing CD, 71% (10/14) of patients had no drainage and 7% (1/14) had reduced drainage 3 months following fibrin glue injection.²² After 2 years, 57% (8/14) of patients in this study had complete fistula closure with no long-term side effects.²² In a subsequent prospective trial, fistula remission rates were significantly higher in the group that received fibrin glue compared with the group that was only observed (38% vs 16%; $P=.04$).²³ Despite these initial promising results, other research has reported significantly lower fistula remission rates.²⁴

Fistula plug placement is another sphincter-sparing technique for perianal fistulas, and is designed to occlude the internal orifice of the tract and to promote healing. The 2 most common types of fistula plugs that are currently being used are bioabsorbable plugs made of lyophilized porcine intestinal submucosa and synthetic plugs made of polyglycolic acid and trimethylene carbonate.² These plugs uniquely elicit minimal foreign body inflammation and essentially prohibit flow through the tract and provide a scaffold for healing. However, the majority of studies evaluating anal plugs are quite small, with variable results and with only a small number of CD patients included. In a systematic review of 20 studies assessing the efficacy of anal fistula plugs, fistula closure was seen in 54.8% (23/42) of patients with underlying CD.²⁵ In a more recent systematic review, complete closure was documented in 58.3% (49/84) of patients with CD, and recurrence occurred in 13.6% (3/22) of the cohort.²⁶ Success rates were higher in patients who received a bioabsorbable plug compared with a synthetic plug.²⁶ Failure of anal plugs is often associated with plug extrusion, which occurs in approximately 8% of patients.^{25,27}

Fistula Laser Closure The use of laser therapy to treat fistulizing CD was first described in 2006 and revisited in 2011, with a pilot study using a fistula laser closure system (FiLaC, BioLitec).^{28,29} FiLaC uses a radial probe to cause denaturation and scarring along the fistula, obliterating the tract.^{8,30} Giamundo and colleagues³¹ were the first to study fistula laser closure in patients with CD-

associated perianal fistulas. The researchers documented an overall healing rate of 72% and recurrence in 5.7% of patients, and concluded that the placement of a loose draining seton prior to laser therapy was associated with better results.³¹ A follow-up study assessing long remission in patients with CD treated with FiLaC found that 69.2% (9/13) of patients maintained complete fistula closure for 5 years.³²

Ligation of Intersphincteric Fistula Tract Procedure

The ligation of intersphincteric fistula tract (LIFT) procedure is a sphincter-sparing operation for the definitive management of patients with complex perianal fistulas. The procedure involves opening the intersphincteric groove, dissecting down to the fistulous tract, and ligating the tract with interrupted sutures.² A systematic review evaluating the efficacy of the LIFT procedure for any type of fistula found primary healing rates from 47% to 95%.³³ Of the 26 studies included, 1 was focused specifically on patients with CD. In this study, complete healing was seen in 60% (9/15) of patients at 2 months' follow-up and in 67% (8/12) of patients at 1 year.³⁴ Predictors of surgical failure included midline fistulas and shorter fistula tracts.³⁴ In a follow-up study, long-term healing was seen in 48% of patients, with a median time to failure of 9 months.³⁵ Recently, a meta-analysis was presented in poster form that compared endorectal advancement flaps with the LIFT procedure and included patients with CD-associated fistulas.³⁶ Of the 74 patients with CD, weighted success and recurrence rates were not significantly different between the LIFT and endorectal advancement flap groups (66% vs 71% and 31% vs 29%, respectively).³⁶ Postoperative incontinence rates were significantly higher in patients who underwent an endorectal advancement flap (7.8%) compared with patients who underwent the LIFT procedure (1.6%).³⁶ Prospective, comparative studies that focus on patients with perianal CD are needed to better understand how the LIFT procedure compares to other sphincter-sparing options.

Video-Assisted Anal Fistula Treatment Video-assisted anal fistula treatment (VAAFT) is one of the newest techniques for patients with perianal fistulas. First described in 2011, this technique consists of an initial diagnostic phase followed by the operative phase.³⁷ The fistulascope (Karl Storz GmbH) is introduced through the external opening of the fistula to outline the anatomy of the tract. The electrode probe is then advanced through the external opening, cauterizing the fistula tract every 1 cm in a circular fashion as the device progresses. Finally, the internal opening is sutured with a stapler device.^{2,30} The initial trial utilizing VAAFT included 136 patients,

although none had CD-related fistulas.³⁷ In a subsequent case series, Schwandner³⁸ evaluated the use of VAAFT on patients with CD-associated fistulas. Complete fistula healing was seen in 82% (9/11) of patients; however, all of these patients underwent a concomitant endorectal advancement flap, and 4 patients also underwent a fecal diversion.³⁸ Benefits of the VAAFT procedure include the direct visualization of the fistula tract, the ability to identify secondary tracts that might be lost with palpation, and high rates of healing without loss of continence. However, the equipment for VAAFT is expensive and the actual surgical procedure is lengthy, suggesting that further studies are needed to better evaluate the optimal use of this technology.^{2,30}

Fecal Diversion Despite aggressive medical and surgical management, complete fistula healing is not achieved in all patients with perianal CD. In these patients, temporary diverting procedures can reduce inflammation and potentially avoid a proctectomy. In a study of fecal diversion in patients with fistulizing CD, Galandiuk and colleagues found that 62% (53/86) of patients in their study required a temporary fecal diversion at some point in their treatment.³⁹ However, the effectiveness of temporary fecal diversion is variable. A systematic review of the long-term outcomes of fecal diversion in patients with perianal CD found that 63.8% of patients had fistula healing.⁴⁰ Restoration of bowel continuity was attempted in 34.5% of patients but was only successful in 16.6%, and 41.6% of patients required a complete proctectomy.⁴⁰

Emerging Endoscopic Techniques

Whereas traditional therapy for perianal CD has included both medical and surgical management, the role of novel endoscopic therapies is now being studied.⁴¹ Endoscopic techniques for patients with perianal fistulas can be both diagnostic and therapeutic. Evaluation using an endoscope can include traditional visualization of the mucosa and identifying inflammation and any associated anal strictures. In addition, newer techniques using guidewires and spray catheters allow endoscopists to identify the internal orifice of the fistula tract.² Endoscopic ultrasound can also be used to help define the anatomy of a fistula, as well as identify any associated abscesses.² Endoscopic fistulotomy is a new technique that uses a needle knife or isolated top knife to open the fistula tract and deploy endoclips along the tract to prevent reformation of the fistula.² Early research has suggested that the best results are seen in fistulas that are short, located in the distal bowel or perianal area, and are extrasphincteric.⁴¹ Endoscopic incision and drainage of perianal abscesses prevents the need for an additional surgical procedure and may allow access

to abscesses that were previously difficult to reach.² Setons can be placed over a guidewire under direct visualization, and a preliminary study suggested that this modality is most successful in patients who have had a previous seton, as the tract is well epithelialized.² As discussed previously, fibrin glues and anal plugs have been placed by surgeons for many years; however, these agents can also be delivered endoscopically. To close the internal opening of a fistula tract, endoscopic clipping and suturing have been studied. A small retrospective study using a proctology clip system (OTSC Proctology, Ovesco Endoscopy AG) in patients with CD reported fistula closure in 70% (7/10) of patients.⁴² Through-the-scope clips have also been used to close fistulas and anastomotic leaks; however, their use has not been formally evaluated in patients with fistulizing CD.⁴¹ Large prospective studies are needed to better define the role of endoscopic therapy in a multidisciplinary approach for patients with perianal fistulizing disease.

Future Therapies

Cell-Based Therapies

The use of allogeneic and autologous adult mesenchymal stem cells (MSCs) to induce fistula healing in patients with perianal CD is being studied. MSCs are commonly isolated from adipose tissue or bone marrow and have been shown to downregulate the immune system and promote tissue repair. Early phase 1, 2, and 3 studies on the use of MSCs in patients with CD-associated perianal fistulas have demonstrated both efficacy and safety.⁴³⁻⁴⁶ In the first phase 1 clinical trial to evaluate the safety of MSCs in patients with fistulizing CD, healing was reported in 75% (3/4) of patients at 8 weeks without any adverse events.⁴⁵ The same research group then performed a phase 2 trial comparing autologous adipose tissue–derived MSCs with fibrin glue alone.⁴⁷ Fistula healing was reported in 71% of patients who were treated with MSCs compared with 17% of patients who received fibrin glue.⁴⁷ In a large, multicenter, phase 3 trial, patients who received autologous adipose tissue–derived MSCs had higher rates of healing at 24 and 52 weeks of therapy compared with controls; however, this difference was not statistically significant.⁴⁸ Given the successful use of fistula plugs and fibrin glue discussed previously, researchers at the Mayo Clinic developed a novel fistula plug impregnated with autologous adipose tissue–derived MSCs (Gore Bio-A Fistula Plug, W. L. Gore and Associates). The research group completed a phase 1 trial utilizing this new plug and reported complete healing in 83% of patients after 6 months (Table).⁴⁹

Although the majority of studies on cell-based therapies have used autologous stem cells, some researchers

Table. Cell-Based Therapies for the Treatment of Perianal Fistulas

Study	Cell Type	Study Type	Number of Patients	Findings
Lee et al ⁴³	Autologous adipose tissue–derived SCs	Phase 2 clinical trial	43	82% (27/33) of patients showed complete fistula healing at 8 weeks after the final injection of SCs.
Ciccocioppo et al ⁴⁴	Autologous bone marrow–derived SCs	Prospective	12	58% (7/12) of patients had complete fistula closure, and 25% (3/12) had incomplete closure of the fistula tract.
García-Olmo et al ⁴⁵	Autologous adipose tissue–derived SCs	Phase 1 clinical trial	9	Complete closure of the fistula (epithelialization) was observed in 67% (6/9) of fistulas.
Cho et al ⁴⁶	Autologous adipose tissue–derived SCs	Phase 2 clinical trial	10	60% (6/10) of patients had complete fistula healing.
García-Olmo et al ⁴⁷	Autologous adipose tissue–derived SCs	Phase 2 clinical trial	24	Complete fistula healing was observed in 71% (17/24) of patients who received SCs with fibrin glue compared to 17% (4/24) of patients who received fibrin glue alone ($P<.001$).
Herreros et al ⁴⁸	Autologous adipose tissue–derived SCs	Phase 3 clinical trial	200	After 26 weeks, the fistula healing rate was 39.1% in patients who received SCs alone, 43.3% in patients who received SCs plus fibrin glue, and 37.3% in patients who received fibrin glue alone.
Dietz et al ⁴⁹	Autologous SCs with a bioabsorbable matrix	Phase 1 clinical trial	12	83% (10/12) of patients had complete clinical healing and radiographic signs of healing at 6 months.
Pánes et al ⁵⁰	Allogeneic adipose tissue–derived SCs	Phase 3 clinical trial	212	51% (53/103) of patients treated with SCs had clinical remission compared with 34% (36/105) of patients who received placebo ($P=.024$).

SC, stem cell.

have successfully implanted allogeneic cells in patients with fistulizing CD (Table). In 2016, a large multicenter trial was performed evaluating the use of allogeneic adipose tissue–derived MSCs.⁵⁰ This study identified a statistically significant difference in healing rates in patients who received MSCs (51%) compared with patients who received saline injection (34%).⁵⁰ Study results are promising and suggest that cell-based therapies are effective and safe in patients with fistulizing CD. Variability in the results from these trials is likely attributable to different techniques in preparation and delivery of the cells, variable skill levels of the physicians injecting the cells, and a lack of standardization in the definition of healing. Continued investigation on the use of MSCs in perianal disease is necessary, as this technique could potentially change the algorithm for the treatment of fistulizing CD.

Novel Biologic Agents

Numerous biologic agents are currently under investigation for the treatment of inflammatory bowel disease, many of which may ultimately be effective for patients with fistulizing disease. To date, novel drugs being studied include SMAD7 antisense oligonucleotides such as

mongersen (GED-0301, Celgene), sphingosine-1-phosphate receptor-1 selective agonists such as ozanimod (RPC-1063, Celgene), selective lymphocyte trafficking inhibitors similar to vedolizumab such as etrolizumab (Genentech), and monoclonal antibodies against novel targets such as interleukin-36. The efficacy of these novel biologic agents in inducing healing of perianal fistulas remains to be seen.

Innovative Surgical Techniques

Modifications to the LIFT procedure have been described in an attempt to improve rates of complete fistula healing. The use of bioprosthetic grafts or an additional plug to reinforce the LIFT procedure (BioLIFT and LIFT-plug, respectively) are 2 of the newer techniques reported in the literature, although there is limited evidence in patients with fistulas secondary to CD.⁵¹ A study evaluating the use of the BioLIFT procedure combined with a mesh biologic prosthesis (Surgisis, Cook Surgical Inc) reported complete healing in 94% of patients, including some patients with underlying CD.^{51,52} Han and colleagues combined the traditional LIFT procedure with an excision of a small portion of the tract and a fistula plug using a human acellular dermal matrix, and found fistula healing in 95% of

patients.^{51,53} Although this study was small, a larger, randomized, multicenter trial comparing the LIFT-plug to the traditional LIFT procedure was performed; however, the results are yet to be published.⁵¹ Further studies on these novel surgical procedures in patients with perianal fistulizing CD are necessary to better define their role both as monotherapy as well as in combination with the various medical therapies available.

Conclusion

The management of perianal fistulizing disease remains a clinical challenge despite significant advances in the treatment of luminal CD over the past decade. The use of biologic therapy and novel surgical techniques appeared to change the treatment algorithm. Although numerous large randomized, controlled trials have been conducted on CD therapies, research on the management of perianal fistulas is limited and mostly made up of open-label cohorts, case series, and subgroup analyses of larger studies. Furthermore, the majority of the trials evaluating the various new surgical techniques excluded patients with perianal fistulas secondary to CD. However, the numerous smaller studies on patients with fistulizing CD to date do offer promise for many of the medical and surgical therapies available. Some of the more innovative techniques, such as the novel endoscopic procedures, may only be available at large, academic, tertiary care centers; however, research and education can help these therapies to become available to a broader community of patients. No gold-standard treatment for perianal fistulas currently exists, but there is value in a therapeutic relationship between gastroenterologists, endoscopists, and colorectal surgeons. Ultimately, an approach including novel medical therapies and modern surgical techniques will likely offer patients with perianal fistulizing CD the most promise in the future.

The authors have no relevant conflicts of interest to disclose.

References

- Safar B, Sands D. Perianal Crohn's disease. *Clin Colon Rectal Surg.* 2007;20(4):282-293.
- Kotze PG, Shen B, Lightner A, et al. Modern management of perianal fistulas in Crohn's disease: future directions. *Gut.* 2018;67(6):1181-1194.
- Sica GS, Di Carlo S, Tema G, et al. Treatment of peri-anal fistula in Crohn's disease. *World J Gastroenterol.* 2014;20(37):13205-13210.
- Schwartz DA, Loftus EV Jr, Tremaine WJ, et al. The natural history of fistulizing Crohn's disease in Olmsted County, Minnesota. *Gastroenterology.* 2002;122(4):875-880.
- Gold SL, Cohen-Mekelburg S, Schneider Y, Steinlauf A. Perianal fistulas in patients with Crohn's disease, part 1: current medical management. *Gastroenterol Hepatol (NY).* 2018;14(8):470-481.
- Marzo M, Felice C, Pugliese D, et al. Management of perianal fistulas in Crohn's disease: an up-to-date review. *World J Gastroenterol.* 2015;21(5):1394-1403.
- Sandborn WJ, Fazio VW, Feagan BG, Hanauer SB; American Gastroenterological Association Clinical Practice Committee. AGA technical review on perianal Crohn's disease. *Gastroenterology.* 2003;125(5):1508-1530.
- Bubbers EJ, Cologne KG. Management of complex anal fistulas. *Clin Colon Rectal Surg.* 2016;29(1):43-49.
- Izadpanah A, Rezazadehkermani M, Hosseini SM, et al. Pulling seton: combination of mechanisms. *Adv Biomed Res.* 2016;5:68.
- Subhas G, Gupta A, Balaraman S, Mittal VK, Pearlman R. Non-cutting setons for progressive migration of complex fistula tracts: a new spin on an old technique. *Int J Colorectal Dis.* 2011;26(6):793-798.
- Bouchard D, Abramowitz L, Bouguen G, et al. Anoperineal lesions in Crohn's disease: French recommendations for clinical practice. *Tech Coloproctol.* 2017;21(9):683-691.
- Bouguen G, Siproudhis L, Gizard E, et al. Long-term outcome of perianal fistulizing Crohn's disease treated with infliximab. *Clin Gastroenterol Hepatol.* 2013;11(8):975-981.e1-e4.
- Ritchie RD, Sackier JM, Hodde JP. Incontinence rates after cutting seton treatment for anal fistula. *Colorectal Dis.* 2009;11(6):564-571.
- Regueiro M, Mardini H. Treatment of perianal fistulizing Crohn's disease with infliximab alone or as an adjunct to exam under anesthesia with seton placement. *Inflamm Bowel Dis.* 2003;9(2):98-103.
- Topstad DR, Panaccione R, Heine JA, Johnson DR, MacLean AR, Buie WD. Combined seton placement, infliximab infusion, and maintenance immunosuppressives improve healing rate in fistulizing anorectal Crohn's disease: a single center experience. *Dis Colon Rectum.* 2003;46(5):577-583.
- Talbot C, Sagar PM, Johnston MJ, Finan PJ, Burke D. Infliximab in the surgical management of complex fistulating anal Crohn's disease. *Colorectal Dis.* 2005;7(2):164-168.
- Mizrahi N, Wexner SD, Zmora O, et al. Endorectal advancement flap: are there predictors of failure? *Dis Colon Rectum.* 2002;45(12):1616-1621.
- Jones IT, Fazio VW, Jagelman DG. The use of transanal rectal advancement flaps in the management of fistulas involving the anorectum. *Dis Colon Rectum.* 1987;30(12):919-923.
- Sonoda T, Hull T, Piedmonte MR, Fazio VW. Outcomes of primary repair of anorectal and rectovaginal fistulas using the endorectal advancement flap. *Dis Colon Rectum.* 2002;45(12):1622-1628.
- Makowicz F, Jehle EC, Becker HD, Starlinger M. Clinical course after trans-anal advancement flap repair of perianal fistula in patients with Crohn's disease. *Br J Surg.* 1995;82(5):603-606.
- Joo JS, Weiss EG, Noguera JJ, Wexner SD. Endorectal advancement flap in perianal Crohn's disease. *Am Surg.* 1998;64(2):147-150.
- Vitton V, Gasmi M, Barthet M, Desjeux A, Orsoni P, Grimaud JC. Long-term healing of Crohn's anal fistulas with fibrin glue injection. *Aliment Pharmacol Ther.* 2005;21(12):1453-1457.
- Grimaud JC, Munoz-Bongrand N, Siproudhis L, et al; Groupe d'Etude Thérapeutique des Affections Inflammatoires du Tube Digestif. Fibrin glue is effective healing perianal fistulas in patients with Crohn's disease. *Gastroenterology.* 2010;138(7):2275-2281.e1.
- Adegbola SO, Pisani A, Sahnun K, Tozer P, Ellul P, Warusavitarne J. Medical and surgical management of perianal Crohn's disease. *Ann Gastroenterol.* 2018;31(2):129-139.
- O'Riordan JM, Datta I, Johnston C, Baxter NN. A systematic review of the anal fistula plug for patients with Crohn's and non-Crohn's related fistula-in-ano. *Dis Colon Rectum.* 2012;55(3):351-358.
- Nasseri Y, Cassella L, Berns M, Zaghiyan K, Cohen J. The anal fistula plug in Crohn's disease patients with fistula-in-ano: a systematic review. *Colorectal Dis.* 2016;18(4):351-356.
- Al-Maawali AK, Nguyen P, Phang PT. Modern treatments and stem cell therapies for perianal Crohn's fistulas. *Can J Gastroenterol Hepatol.* 2016;2016:1651570.
- Moy J, Bodzin J. Carbon dioxide laser ablation of perianal fistulas in patients with Crohn's disease: experience with 27 patients. *Am J Surg.* 2006;191(3):424-427.
- Wilhelm A. A new technique for sphincter-preserving anal fistula repair using a novel radial emitting laser probe. *Tech Coloproctol.* 2011;15(4):445-449.
- Limura E, Giordano P. Modern management of anal fistula. *World J Gastroenterol.* 2015;21(1):12-20.
- Giamundo P, Geraci M, Tibaldi L, Valente M. Closure of fistula-in-ano with laser—FiLaC™: an effective novel sphincter-saving procedure for complex disease. *Colorectal Dis.* 2014;16(2):110-115.
- Wilhelm A, Fiebig A, Krawczak M. Five years of experience with the FiLaC™ laser for fistula-in-ano management: long-term follow-up from a single institution. *Tech Coloproctol.* 2017;21(4):269-276.
- Sirany AM, Nygaard RM, Morken JJ. The ligation of the intersphincteric

- fistula tract procedure for anal fistula: a mixed bag of results. *Dis Colon Rectum*. 2015;58(6):604-612.
34. Gingold DS, Murrell ZA, Fleshner PR. A prospective evaluation of the ligation of the intersphincteric tract procedure for complex anal fistula in patients with Crohn's disease. *Ann Surg*. 2014;260(6):1057-1061.
35. Kamiński JP, Zaghiyan K, Fleshner P. Increasing experience of ligation of the intersphincteric fistula tract for patients with Crohn's disease: what have we learned? *Colorectal Dis*. 2017;19(8):750-755.
36. Stellingwerf ME, van Praag EM, Bemelman WA, Buskens CJ. Meta-analysis of endorectal advancement flap vs. ligation of the intersphincteric fistula tract for Crohn's and cryptoglandular high perianal fistulas. Poster presented at: 13th Congress of ECCO; February 14-17, 2018; Vienna, Austria. Abstract P426.
37. Meinero P, Mori L. Video-assisted anal fistula treatment (VAAFT): a novel sphincter-saving procedure for treating complex anal fistulas. *Tech Coloproctol*. 2011;15(4):417-422.
38. Schwandner O. Video-assisted anal fistula treatment (VAAFT) combined with advancement flap repair in Crohn's disease. *Tech Coloproctol*. 2013;17(2):221-225.
39. Galandiuk S, Kimberling J, Al-Mishlab TG, Stromberg AJ. Perianal Crohn disease: predictors of need for permanent diversion. *Ann Surg*. 2005;241(5):796-801; discussion 801-802.
40. Singh S, Ding NS, Mathis KL, et al. Systematic review with meta-analysis: faecal diversion for management of perianal Crohn's disease. *Aliment Pharmacol Ther*. 2015;42(7):783-792.
41. Shen B. Exploring endoscopic therapy for the treatment of Crohn's disease-related fistula and abscess. *Gastrointest Endosc*. 2017;85(6):1133-1143.
42. Mennigen R, Laukötter M, Senninger N, Rijcken E. The OTSC(*) proctology clip system for the closure of refractory anal fistulas. *Tech Coloproctol*. 2015;19(4):241-246.
43. Lee WY, Park KJ, Cho YB, et al. Autologous adipose tissue-derived stem cells treatment demonstrated favorable and sustainable therapeutic effect for Crohn's fistula. *Stem Cells*. 2013;31(11):2575-2581.
44. Ciccocioppo R, Bernardo ME, Sgarella A, et al. Autologous bone marrow-derived mesenchymal stromal cells in the treatment of fistulising Crohn's disease. *Gut*. 2011;60(6):788-798.
45. García-Olmo D, García-Arranz M, Herreros D, Pascual I, Peiro C, Rodríguez-Montes JA. A phase I clinical trial of the treatment of Crohn's fistula by adipose mesenchymal stem cell transplantation. *Dis Colon Rectum*. 2005;48(7):1416-1423.
46. Cho YB, Lee WY, Park KJ, Kim M, Yoo HW, Yu CS. Autologous adipose tissue-derived stem cells for the treatment of Crohn's fistula: a phase I clinical study. *Cell Transplant*. 2013;22(2):279-285.
47. García-Olmo D, Herreros D, Pascual I, et al. Expanded adipose-derived stem cells for the treatment of complex perianal fistula: a phase II clinical trial. *Dis Colon Rectum*. 2009;52(1):79-86.
48. Herreros MD, García-Arranz M, Guadalajara H, De-La-Quintana P, García-Olmo D; FATT Collaborative Group. Autologous expanded adipose-derived stem cells for the treatment of complex cryptoglandular perianal fistulas: a phase III randomized clinical trial (FATT 1: Fistula Advanced Therapy Trial 1) and long-term evaluation. *Dis Colon Rectum*. 2012;55(7):762-772.
49. Dietz AB, Dozois EJ, Fletcher JG, et al. Autologous mesenchymal stem cells, applied in a bioabsorbable matrix, for treatment of perianal fistulas in patients with Crohn's disease. *Gastroenterology*. 2017;153(1):59-62.e2.
50. Panés J, García-Olmo D, Van Assche G, et al; ADMIRE CD Study Group Collaborators. Expanded allogeneic adipose-derived mesenchymal stem cells (Cx601) for complex perianal fistulas in Crohn's disease: a phase 3 randomised, double-blind controlled trial. *Lancet*. 2016;388(10051):1281-1290.
51. DeBarros MM, Sohn VY, Steele SR. Future directions in the management of anal fistula. *Semin Colon Rectal Surg*. 2014;(25):228-232.
52. Ellis CN. Outcomes with the use of bioprosthetic grafts to reinforce the ligation of the intersphincteric fistula tract (BioLIFT procedure) for the management of complex anal fistulas. *Dis Colon Rectum*. 2010;53(10):1361-1364.
53. Han JG, Yi BQ, Wang ZJ. Ligation of the intersphincteric fistula tract plus a bioprosthetic anal fistula plug (LIFT-Plug): a new technique for fistula-in-ano. *Colorectal Dis*. 2013;15(5):582-586.