

Hepatitis B Virus Infection and Organ Transplantation

Walid S. Ayoub, MD, Paul Martin, MD, and Kalyan Ram Bhamidimarri, MD

Dr Ayoub is a clinical associate professor of medicine in the Department of Digestive and Liver Diseases and an assistant medical director of the Liver Transplant Program at Cedars-Sinai Medical Center in Los Angeles, California. Dr Martin is a professor of medicine and Dr Bhamidimarri is an associate professor of medicine in the Division of Gastroenterology and Hepatology at the University of Miami Miller School of Medicine in Miami, Florida.

Address correspondence to:

Dr Walid S. Ayoub
Cedars-Sinai Medical Center
Department of Digestive and Liver Diseases
8900 Beverly Blvd
Los Angeles, CA 90048
Tel: 310-423-1971
Fax: 310-423-2356
E-mail: Walid.Ayoub@cshs.org

Keywords

Transplantation, hepatitis B core antibody, hepatitis B virus reactivation, hepatitis B virus recurrence

Abstract: Hepatitis B virus (HBV) infection remains an important cause of liver disease and continues to present several unique challenges in organ transplantation despite the availability of an effective vaccine to prevent HBV infection and the introduction of oral therapy to treat HBV infection over 20 years ago. HBV recurrence following liver transplantation can now be prevented with antiviral therapy, although controversy persists as to whether immunoprophylaxis with hepatitis B immunoglobulin is also necessary. HBV reactivation following organ transplantation can occur even in recipients with absent hepatitis B surface antigen at the time of transplantation and remains an important cause of morbidity and mortality. Expansion of the donor pool by using organs from hepatitis B core antibody–positive donors can result in HBV infection in the recipient. Another challenge is severe HBV reactivation leading to liver failure in HBV-infected patients receiving immunomodulatory agents, which are increasingly being used for a variety of nonneoplastic indications.

Chronic hepatitis B virus (HBV) infection remains a major cause of mortality and morbidity worldwide, accounting for a third of all cases of cirrhosis and half of all cases of hepatocellular carcinoma (HCC).¹ Although it has been suggested that 1.4 million people in the United States are infected with HBV, this number is very likely an underestimate due to undersampling of immigrant communities, which continue to have a high prevalence of HBV infection. The true prevalence of HBV infection in the United States may be closer to 3 million people.² Initial data from the Hepatitis B Research Network (HBRN), a collaboration of 28 clinical centers across the United States and Canada, showed the impact of immigration on HBV prevalence. In a study, the HBRN evaluated 1625 treatment-naïve patients with chronic HBV infection in North America. Study participants were mostly male and had a mean age of 42 years; 72% were Asian, and 82% of the participants were born outside of North America.²

Table 1. Predictors of HBV Recurrence After Liver Transplantation

- Presence of HCC at the time of transplantation
- Anti-HBc–positive graft
- Mutation of the HBV *S* gene
- Elevated HBV viral load at the time of transplantation
- Hepatitis B e antigen positivity
- Immunosuppression

Anti-HBc, hepatitis B core antibody; HBV, hepatitis B virus; HCC, hepatocellular carcinoma.

Liver Transplantation With Donors or Recipients Who Have Hepatitis B Virus Infection

Currently, approved oral therapy for HBV infection is merely suppressive rather than curative due to the persistence of HBV covalently closed circular DNA (cccDNA) in infected hepatocytes even if hepatitis B surface antigen (HBsAg) clearance occurs in the serum. However, the use of these oral agents since the mid-1990s has had a major impact on the natural history of chronic HBV infection, as decompensated cirrhosis due to HBV infection has become an uncommon indication for liver transplantation. Nevertheless, HCC complicating chronic HBV infection remains an important indication, as does acute liver failure due to acute HBV infection or reactivation. The course of HBV infection posttransplant was characterized even before the development of effective prophylactic strategies.³ Circulating HBV virions from extrahepatic reservoirs rapidly entered graft hepatocytes with the occurrence of liver injury within several weeks of transplant, reflected by elevated aminotransferase levels. Progressive graft injury then typically occurred, often culminating in graft failure within 1 or 2 years of transplant. The median time to reinfection after liver transplantation was 145 days (range, 15–2615 days), with a few cases progressing to fibrosing cholestatic hepatitis and death within 1 year of transplantation.⁴ HBV recurrence has also been linked to early acute cellular rejection within 30 days of transplantation, although this observation may be less likely with the current immunosuppressive regimens.³

There are multiple predictors of HBV recurrence after liver transplantation (Table 1). Patients with an elevated viral load at the time of transplantation, hepatitis B e antigen positivity, or a history of drug resistance to oral HBV therapy are considered to be at higher risk of HBV recurrence.³ The presence of HCC at the time of transplantation, HCC recurrence after liver transplantation, chemotherapy for HCC, hepatitis B core antibody

(anti-HBc)-positive grafts, and mutation of the HBV *S* gene are also risk factors for HBV infection in the graft.⁵ Patients with a low viral load, hepatitis B e antigen–negative status, acute liver failure, or hepatitis D virus coinfection are at low risk for recurrent HBV infection after liver transplantation. Immunosuppression after liver transplantation can also induce viral replication even in patients with isolated anti-HBc positivity or in patients who receive anti-HBc–positive grafts, despite these patients being HBsAg–negative and hepatitis B surface antibody (anti-HBs)–positive.^{6,7} In such a situation, HBV reinfection results from immediate infection of the hepatocytes by circulating HBV particles or later reinfection from HBV particles coming from extrahepatic sites such as peripheral blood mononuclear cells.³

Hepatitis B immunoglobulin (HBIG) is a human-derived polyclonal antibody against the AGL domain of the HBsAg L protein. Although the mechanism of action of HBIG is not completely understood, its actions include binding circulating viral particles by immune complex formation, preventing infection of hepatocytes by blocking the HBV receptor, and preventing HBsAg secretion after undergoing endocytosis by hepatocytes.^{3,8}

In the absence of effective antiviral therapy, the administration of HBIG alone in a transplant recipient was associated with lower HBV recurrence (30%) and improved survival (80%) at 5 years, compared to 80% HBV recurrence and 50% survival if no HBIG was given.⁹ The addition of an oral nucleos(t)ide analogue (NA) to HBIG post–liver transplantation resulted in a significant decline of HBV recurrence and also a significant improvement in prognosis.⁹ Not only was the outcome of HBV-related liver transplantation changed with the introduction of the NA but also the natural history of chronic HBV infection was interrupted with subsequent improvement in hepatocellular function and even regression of cirrhosis.¹⁰ The impact of NA therapy is also reflected by the decreasing frequency of HBV cirrhosis as an indication for liver transplantation. Burra and colleagues analyzed the European Liver Transplant Registry database across 20 years of HBV-related liver transplantation, and found a decreased trend in decompensated cirrhosis from 84.2% in 1988 through 1995 to 70.4% in 2006 through 2010 but a doubling of chronic HBV/HCC from 15.8% to 29.6% ($P < .001$) between the same time periods.¹¹

The outcome of HBV-related liver transplantation has experienced further improvement with the addition of NA therapy to HBIG so that 5-year survival for HBV-related liver transplantation is now similar to that of other indications for liver transplantation. However, not all NAs are equal in regard to efficacy and resistance profile (Table 2). The addition of a NA with a high genetic

Table 2. Oral Agents for the Prevention of HBV Recurrence

High Genetic Barrier to Resistance	Low Genetic Barrier to Resistance
<ul style="list-style-type: none"> • Tenofovir • Entecavir 	<ul style="list-style-type: none"> • Lamivudine • Adefovir

HBV, hepatitis B virus.

barrier to resistance, such as entecavir and tenofovir, to HBIG results in lower post-liver transplantation HBV recurrence than lamivudine or adefovir monotherapy. After a median follow-up of 30 months (range, 8-38 months), HBV recurrence (defined by HBsAg positivity) was 6.1% and 1.0% ($P=.0004$) in patients who received HBIG plus lamivudine or HBIG plus entecavir/tenofovir, respectively.⁸ First-line NA therapy cannot be used solely without HBIG in the early phase after liver transplantation. Patients who received first-line NA monotherapy post-liver transplantation had more recurrence (HBsAg positivity) after a median follow-up of 23 months (range, 20-26 months), compared to patients who received HBIG plus lamivudine (26.0% vs 5.9%; $P<.0001$). Early withdrawal of HBIG and continuation of first-line NA therapy is becoming the standard, as HBV recurrence post-liver transplantation is significantly lower than in patients receiving HBIG plus lamivudine.⁸

Several studies have documented the persistence of HBV DNA in the serum, liver, and peripheral blood mononuclear cells even 10 years after liver transplantation.¹²⁻¹⁴ Such HBV reservoirs can become a source of reinfection even in HBsAg-negative recipients. Therefore, lifelong prophylactic therapy for HBV infection is recommended after liver transplantation.¹⁵ Recent study analysis has recommended stratifying patients into low- and high-risk groups at the time of transplantation. The low-risk group consists of patients with undetectable HBV DNA, and the high-risk group consists of patients with detectable HBV DNA, the presence of drug-resistant HBV infection, HIV or hepatitis D virus coinfection, HCC at liver transplantation, or a history of poor compliance to HBV therapy. HBIG-free therapy with either entecavir or tenofovir indefinitely is currently the most preferred strategy in this setting. The high-risk group requires HBIG from the anhepatic phase to 1 year after liver transplantation, with a target anti-HBs level greater than 100 mIU/mL, in addition to a first-line NA.³

Recurrence of HBV infection post-liver transplantation has been suggested to be a factor for HCC recurrence. Campsen and colleagues conducted a study

on the predictors of recurrent HCC post-liver transplantation.¹⁶ The study design included 3 eras based upon the evolution and availability of anti-HBV therapies. Post-liver transplantation recurrence of HCC was elevated in those who had a higher tumor burden prior to liver transplantation and in those who had HBV reinfection. It was interesting to note that not all patients with HBV reinfection developed HCC, but all HCC recurrences occurred only in those with HBV reinfection.¹⁶ Also interesting was that recent studies have shown higher HBsAg expression and HBV DNA load in peritumoral tissue than inside HCC tissue in patients positive for HCC.¹⁷ A study from Wu and colleagues showed that larger HCC size (>5 cm), microvascular invasion, and the presence of basal core promoter mutations were independent predictors of HCC recurrence post-liver transplantation.¹⁸ Therefore, patients with HBV-related HCC need to undergo stringent evaluation and staging of HCC prior to liver transplantation, and aggressive antiviral therapy post-liver transplantation is recommended to prevent HBV reinfection.¹⁸

Hepatitis B Core Antibody-Positive Organs and Transplantation

The definition of HBV cure has evolved over time and can be separated into functional cure and virologic, or complete, cure. Functional cure is characterized by sustained loss of HBsAg, the presence of anti-HBc and anti-HBs, and undetectable HBV DNA in the presence of HBV cccDNA. A virologic cure implies clearance of cccDNA from the nucleus of the hepatocyte.¹⁹ Anti-HBc is not completely protective against future reactivation even in the absence of circulating serum HBV DNA due to the persistence of HBV cccDNA in patients with a functional cure. However, to expand the organ donor pool, anti-HBc-positive organs have been used more frequently in recent years, as functional cure is achievable with highly effective NA therapy. As the prevalence of HBV infection varies throughout the world, it is no surprise that the prevalence of anti-HBc also varies in the general population: 2% to 9% in the United States, 7% to 12% in Europe and Japan, and 53% to 57% in China and Taiwan.²⁰ The risk of HBV transmission from anti-HBc-positive and HBsAg-negative graft has been shown to be the highest in liver transplantation, moderate in kidney transplantation, and lowest in thoracic organ transplantation.²⁰ The intensity of the immunosuppressive regimen (especially the use of corticosteroids), prior immunization against HBV infection, and anti-HBs titer levels prior to transplantation have been suggested to influence the rate of HBV transmission from anti-HBc-positive grafts.²⁰

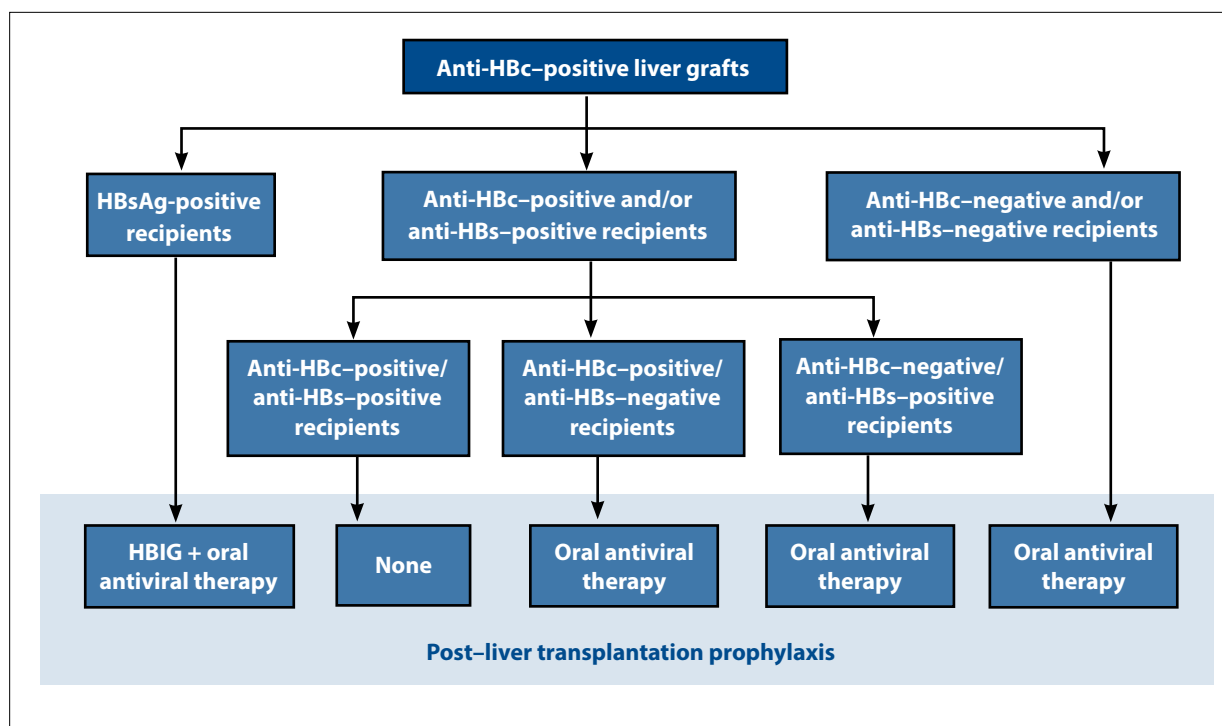


Figure. A summary of prophylaxis recommendations for recipients of anti-HBc-positive liver grafts. Lamivudine is the most cost-effective nucleos(t)ide analogue, but any can be used for prophylaxis in naive patients.³

Anti-HBc, hepatitis B core antibody; anti-HBs, hepatitis B surface antibody; HBIG, hepatitis B immunoglobulin; HBsAg, hepatitis B surface antigen.

Hepatitis B Core Antibody Positivity in Liver Transplantation

The use of anti-HBc-positive organs in liver transplant recipients has been associated with the development of de novo HBV infection. De novo HBV infection is defined by the appearance of HBsAg or HBV DNA. In a study by Yen and colleagues in 2006 on liver transplant recipients who had not received HBIG or other antiviral prophylaxis, the rate of HBV transmission after liver transplantation was 18% in previously vaccinated recipients and 13% in isolated anti-HBc-positive recipients but 0% in recipients with immunity due to prior infection (anti-HBc and anti-HBs positivity).²¹ An analysis of 903 recipients of anti-HBc-positive liver grafts from 39 studies revealed a de novo HBV rate of 48.0% in HBV-naive recipients, 13.1% in those with prior infection without durable anti-HBs (anti-HBc-positive/anti-HBs-negative), and 1.4% in those with positive anti-HBc and anti-HBs.²² A more recent study by Skagen and colleagues demonstrated, in the absence of posttransplant prophylaxis, de novo HBV rates of 18% in previously vaccinated recipients, 14% in isolated anti-HBc-positive recipients, and 4% in anti-HBc- and anti-HBs-positive recipients.²³ Such results have made the long-term use of oral antiviral

therapy the standard in liver transplant recipients of anti-HBc-positive grafts regardless of the HBV serologic profile of the patients. A cost-effectiveness analysis using the Markov model demonstrated that lamivudine remains the most cost-effective approach for preventing de novo HBV infection in recipients of anti-HBc-positive grafts.²⁴ After a median follow-up of 8.6 years, liver-associated morbidity, HCC, and acute rejection were significantly higher in patients with HBV reactivation, compared with patients who did not experience HBV reactivation ($P < .05$).²⁵ A proposed algorithm for the management of recipients of anti-HBc-positive grafts is shown in the Figure.

Hepatitis B Core Antibody Positivity in Kidney Transplantation

De novo HBV infection has also been observed in kidney transplant recipients with positive anti-HBc. In an analysis of 11 retrospective and prospective studies comprising 1385 patients who received kidney transplantation from HBsAg-negative/anti-HBc-positive donors regardless of their anti-HBs status, the rate of HBsAg seroconversion was 0.27% (4/1385). The rate of HBV core seroconversion was 3.24%, and only 0.28% of the patients developed HBsAg antigenemia. However,

none of the patients who experienced HBsAg and HBV core seroconversion experienced symptomatic hepatitis, higher mortality, or decreased survival of the graft.²⁶ In a more recent study of 322 patients with occult HBV infection (negative HBsAg and positive anti-HBc), 4.7% of the recipients developed de novo HBV infection. HBV reactivation also impacted survival of the recipients, with 1-, 3-, 5-, and 10-year patient survival of 87%, 79%, 72%, and 65%, respectively, compared to 96%, 94%, 91.5%, and 84.5%, respectively, in patients without HBV reactivation.²⁵ Having detectable anti-HBs with anti-HBc positivity did not fully protect against HBV reactivation, as 13.3% (2/15) experienced HBV reactivation compared to 42% (129/307) in the anti-HBc-positive/anti-HBs-negative group. Logistic regression in this analysis revealed that anti-HBs positivity before transplantation as well as lamivudine prophylaxis were independent protective factors against HBV reactivation (odds ratio [OR], 0.046 and 0.038; $P < .05$). Patients older than 60 years and those who received anti-T-cell antibody immunosuppressive agents were associated with an increased risk of HBV reactivation (OR, 11.69 and 4.87, respectively).²⁵

HBV vaccination of anti-HBc-positive renal transplant recipients with a target anti-HBs titer greater than 10 IU/L has been proven to be protective against HBV reactivation.²⁰ It is unknown whether a higher anti-HBs titer can offer further protection. However, an older study from 2006 reported a decrease in the risk of anti-HBc seroconversion to 4% with an anti-HBs titer greater than 100 IU/L, compared to a risk of 10% with an anti-HBs titer less than 100 IU/L.²⁷

Hepatitis B Core Antibody Positivity in Thoracic Organ Transplantation

The use of an anti-HBc-positive donor graft does not appear to have an impact on long-term survival of the recipient.²⁰ Historically, the incidence of de novo HBV infection from anti-HBc-positive organs was reported to be 3% in a study of 33 patients, of whom 5 patients received lamivudine prophylaxis.²⁸ Dhillon and colleagues performed an analysis of 13,233 recipients of anti-HBc-negative organs and 333 recipients of anti-HBc-positive organs for lung and combined heart-lung transplantation.²⁹ Anti-HBc-positive donor status had no impact on 5-year mortality in multivariate analysis but was associated with a higher 1-year mortality in unadjusted analysis. The authors postulated that 1-year unadjusted mortality could have been impacted by the severity of decompensation prior to transplantation.

Data are scarce regarding the impact of pre-transplant HBV vaccination or the use of lamivudine posttransplantation on the rate of de novo HBV infection.

One study described 29 recipients of lung transplant from anti-HBc-positive donors who completed HBV vaccination. No HBV transmission was observed, and the vaccinated group had 1-year survival comparable to that of the anti-HBc-negative group. However, the response to vaccination or the anti-HBs titer was not reported in this study.³⁰ A study of 7 patients who had 1 year of lamivudine therapy after receiving an anti-HBc-positive donor lung revealed no incidence of de novo HBV infection. However, information regarding the prior vaccination status and HBV serostatus of recipients was not available in this study.³¹

Kidney Transplantation From Donors With Hepatitis B Virus Infection

The introduction of antiviral therapy has improved survival of renal transplant recipients with HBsAg positivity. Previously, the presence of HBsAg positivity in a recipient was associated with a 2.49-fold higher risk of death after kidney transplantation.³² Successful viral suppression of HBV infection with NA therapy has led to significantly improved survival.³³⁻³⁵ Ridruejo advocated for the treatment of renal transplant candidates with HBsAg positivity and assessment for the presence of liver fibrosis in all candidates.³⁶ Patients with decompensated liver disease and end-stage renal disease should be referred for evaluation for dual liver and kidney transplantation. In patients with positive HBsAg and undetectable HBV DNA, prophylactic therapy is recommended. In patients with HBsAg positivity and HBV DNA less than 2000 IU/mL, preemptive therapy is recommended. In patients with HBV DNA greater than 2000 IU/mL, treatment is recommended.³⁶ Treatment with an antiviral HBV agent with a high genetic barrier to resistance is preferred.

There are growing reports in the literature regarding the safety of HBV-positive organs for kidney transplantation. There have been many proposed strategies to prevent HBV flare posttransplantation, from the administration of a vaccine to the use of HBIG and oral antiviral therapy.²⁰ Most of the recipients in such reports were anti-HBs seropositive. Tuncer and colleagues demonstrated the safety of the use of HBsAg-positive organs in 35 recipients with an anti-HBs titer greater than 10 mIU/mL and negative donor HBV DNA.³⁷ Recipients with an anti-HBs titer less than 10 mIU/mL were vaccinated to raise their titer to greater than 10 mIU/mL. HBIG and lamivudine were not used in this study.³⁷ No recipient developed de novo HBV infection or HBV-attributed complications over the 2-year duration of the study. Another study highlighted the importance of having an anti-HBs titer greater than 100 mIU/mL in HBsAg-negative recipients regardless of the HBsAg status of the donor.³⁸

Table 3. Stages of HBV Reactivation^a

	Stage 1	Stage 2	Stage 3	Stage 4	Stage 5
HBsAg	+	+	+	+	–
AST and ALT	Normal	↑↑	↑↑↑↑	↑↑↑↑	Normal
HBV DNA	↑↑	↑↑↑↑	↑↑↑↑	↑↑↑↑	↓↓↓↓
Total Bilirubin	Normal	Normal	↑↑	↑↑↑↑	Normal
Liver Decompensation	None	None	Jaundice	↑↑ INR, ascites, hepatic encephalopathy	Resolved

The arrows represent the severity of the HBV viremia.

^aNot all patients follow this sequence of progression.

ALT, alanine aminotransferase; AST, aspartate aminotransferase; HBsAg, hepatitis B surface antigen; HBV, hepatitis B virus; INR, international normalized ratio.

Transplantation of a HBsAg-positive graft into a HBsAg-negative patient carries a significant risk of de novo infection without adequate prophylaxis. Despite the protection acquired from HBV vaccination or prior exposure to HBV infection, many centers remain reluctant to use HBsAg-positive grafts.

Hepatitis B Core Antibody Positivity in Patients Receiving Chemotherapy

HBV reactivation can occur as early as 2 weeks after initiation of immunosuppressive therapy to 1 year after the end of therapy. Typically, HBV reactivation progresses in 5 stages, but not all patients follow this sequence of progression (Table 3). In the first stage, a HBsAg-negative patient is asymptomatic and develops HBsAg, followed by a rapid rise in HBV viral replication. This is followed by the second stage, in which the patient’s alanine aminotransferase (ALT) and aspartate aminotransferase (AST) levels start to increase (>5 times baseline values) in the presence of rising HBV viral load. Within several weeks, the patient’s bilirubin level starts to rise, and the patient develops jaundice (the 3rd stage). If no treatment is initiated, the patient can progress to acute liver failure (the 4th stage). This stage is characterized by an increase in international normalized ratio and the development of ascites and hepatic encephalopathy. Once HBV therapy is started, the ALT level and HBV DNA polymerase chain reaction (PCR) start to decline. If there is no improvement, the patient will progress to acute liver failure, and liver transplantation becomes the only option for survival. However, many patients are not candidates for liver transplantation due to their underlying malignancies or comorbidities. The 5th stage is resolution with immune recovery, whereby patients recover after initiation of antiviral therapy and cessation of immunosuppressive therapy.³⁹ Patients at greater risk for

Table 4. Risks of HBV Reactivation in HBsAg-Negative and Anti-HBc-Positive Patients

High Risk
<ul style="list-style-type: none"> • B-cell–depleting agents (rituximab, ofatumumab, natalizumab, alemtuzumab, ibritumomab)
Moderate Risk
<ul style="list-style-type: none"> • High-dose corticosteroids (>20 mg/day orally of prednisone for >4 weeks) • Anthracyclines (doxorubicin, epirubicin) • TNF-α inhibitors (infliximab, adalimumab, certolizumab pegol, golimumab) • Systemic cancer chemotherapy, including for HCC • Cytokine-based therapies (abatacept, vedolizumab, natalizumab, mogamulizumab) • Cyclosporine, tacrolimus • Tyrosine kinase inhibitors (imatinib, nilotinib) • Proteasome inhibitor (bortezomib)
Low Risk
<ul style="list-style-type: none"> • Moderate- and low-dose prednisone (<20 mg/day orally for >4 weeks) • Antimetabolites (azathioprine, 6-mercaptopurine, methotrexate)

Anti-HBc, hepatitis B core antibody; HBsAg, hepatitis B surface antigen; HBV, hepatitis B virus; HCC, hepatocellular carcinoma; TNF, tumor necrosis factor.

Adapted from Loomba and Liang.³⁹

HBV reactivation are those who receive B-cell–depleting therapies as well as bone marrow and solid-organ transplant recipients (Table 4). Patients in high-risk categories should receive HBV suppressive therapy. In most other scenarios, watchful monitoring may be an alternative. The incidence rate of HBV reactivation is at least 10% in the high-risk group and 1% to 10% in the moderate-risk group.³⁹

Table 5. Risk of Transmission of HBV From Anti-HBc–Positive Graft

	Risk of Transmission
Liver Transplant	High
Kidney Transplant	Moderate-high
Thoracic Transplant	Low

Anti-HBc, hepatitis B core antibody; HBV, hepatitis B virus.

Summary

Prevention of HBV recurrence post–liver transplantation is now feasible and has resulted in excellent recipient and graft outcomes. Organs from HBsAg-negative and anti-HBc–positive donors should be considered for adult transplant candidates after a detailed discussion with the recipients regarding the risk-benefit ratio. The risk of HBV transmission varies according to the organ transplanted (Table 5). De novo hepatitis is not common with appropriate use of antiviral therapy. In non–liver transplant recipients, antiviral therapy is recommended for those with vaccine immunity (anti-HBc–negative/anti-HBs–positive).²⁰ For liver transplant recipients, indefinite antiviral therapy is recommended. All transplant candidates should receive HBV vaccination if they are not immune in order to facilitate receipt of an organ from a donor with anti-HBc seropositivity.

Dr Bhamidimarri has been a member of the Scientific Advisory Board for Gilead. The other authors have no relevant conflicts of interest to disclose.

References

- Perz JF, Armstrong GL, Farrington LA, Hutin YJ, Bell BP. The contributions of hepatitis B virus and hepatitis C virus infections to cirrhosis and primary liver cancer worldwide. *J Hepatol*. 2006;45(4):529-538.
- Ghany MG, Perrillo R, Li R, et al; Hepatitis B Research Network. Characteristics of adults in the Hepatitis B Research Network in North America reflect their country of origin and hepatitis B virus genotype. *Clin Gastroenterol Hepatol*. 2015;13(1):183-192.
- Maiwall R, Kumar M. Prevention and treatment of recurrent hepatitis B after liver transplantation. *J Clin Transl Hepatol*. 2016;4(1):54-65.
- Lerut JB, Donataccio M, Ciccarelli O, et al. Liver transplantation and HBsAg-positive postnecrotic cirrhosis: adequate immunoprophylaxis and delta virus co-infection as the significant determinants of long-term prognosis. *J Hepatol*. 1999;30(4):706-714.
- Urabe A, Imamura M, Tsuge M, et al. The relationship between HBcAg and HBV reinfection in HBV related post-liver transplantation patients. *J Gastroenterol*. 2017;52(3):366-375.
- Matsui T, Kang JH, Nojima M, et al. Reactivation of hepatitis B virus in patients with undetectable HBsAg undergoing chemotherapy for malignant lymphoma or multiple myeloma. *J Med Virol*. 2013;85(11):1900-1906.
- Demetris AJ, Jaffe R, Sheahan DG, et al. Recurrent hepatitis B in liver allograft recipients. Differentiation between viral hepatitis B and rejection. *Am J Pathol*. 1986;125(1):161-172.
- Cholongitas E, Papatheodoridis GV. High genetic barrier nucleos(t)ide analogue(s) for prophylaxis from hepatitis B virus recurrence after liver transplantation: a systematic review. *Am J Transplant*. 2013;13(2):353-362.
- Samuel D, Muller R, Alexander G, et al. Liver transplantation in European patients with the hepatitis B surface antigen. *N Engl J Med*. 1993;329(25):1842-1847.
- Marcellin P, Gane E, Buti M, et al. Regression of cirrhosis during treatment with tenofovir disoproxil fumarate for chronic hepatitis B: a 5-year open-label follow-up study. *Lancet*. 2013;381(9865):468-475.
- Burra P, Germani G, Adam R, et al. Liver transplantation for HBV-related cirrhosis in Europe: an ELTR study on evolution and outcomes. *J Hepatol*. 2013;58(2):287-296.
- Lenci I, Marcuccilli F, Tisone G, et al. Total and covalently closed circular DNA detection in liver tissue of long-term survivors transplanted for HBV-related cirrhosis. *Dig Liver Dis*. 2010;42(8):578-584.
- Hussain M, Soldevila-Pico C, Emre S, Luketic V, Lok AS; NIH HBV-OLT Study Group. Presence of intrahepatic (total and ccc) HBV DNA is not predictive of HBV recurrence after liver transplantation. *Liver Transpl*. 2007;13(8):1137-1144.
- Roche B, Feray C, Gigou M, et al. HBV DNA persistence 10 years after liver transplantation despite successful anti-HBs passive immunoprophylaxis. *Hepatology*. 2003;38(1):86-95.
- Lenci I, Tisone G, Di Paolo D, et al. Safety of complete and sustained prophylaxis withdrawal in patients liver-transplanted for HBV-related cirrhosis at low risk of HBV recurrence. *J Hepatol*. 2011;55(3):587-593.
- Campsen J, Zimmerman M, Trotter J, et al. Liver transplantation for hepatitis B liver disease and concomitant hepatocellular carcinoma in the United States with hepatitis B immunoglobulin and nucleoside/nucleotide analogues. *Liver Transpl*. 2013;19(9):1020-1029.
- Jing YY, Liu WT, Guo SW, et al. Hepatitis B virus (HBV) receptors: deficiency in tumor results in scant HBV infection and overexpression in peritumor leads to higher recurrence risk. *Oncotarget*. 2015;6(40):42952-42962.
- Wu TJ, Chan KM, Chou HS, et al. Liver transplantation in patients with hepatitis B virus-related hepatocellular carcinoma: the influence of viral characteristics on clinical outcome. *Ann Surg Oncol*. 2013;20(11):3582-3590.
- Revill P, Testoni B, Locarnini S, Zoulim F. Global strategies are required to cure and eliminate HBV infection. *Nat Rev Gastroenterol Hepatol*. 2016;13(4):239-248.
- Huprikar S, Danziger-Isakov L, Ahn J, et al. Solid organ transplantation from hepatitis B virus-positive donors: consensus guidelines for recipient management. *Am J Transplant*. 2015;15(5):1162-1172.
- Yen RD, Bonatti H, Mendez J, Aranda-Michel J, Satyanarayana R, Dickson RC. Case report of lamivudine-resistant hepatitis B virus infection post liver transplantation from a hepatitis B core antibody donor. *Am J Transplant*. 2006;6(5 pt 1):1077-1083.
- Cholongitas E, Papatheodoridis GV, Burroughs AK. Liver grafts from anti-hepatitis B core positive donors: a systematic review. *J Hepatol*. 2010;52(2):272-279.
- Skagen CL, Jou JH, Said A. Risk of de novo hepatitis in liver recipients from hepatitis-B core antibody-positive grafts—a systematic analysis. *Clin Transplant*. 2011;25(3):E243-E249.
- Wright AJ, Fishman JA, Chung RT. Lamivudine compared with newer antivirals for prophylaxis of hepatitis B core antibody positive livers: a cost-effectiveness analysis. *Am J Transplant*. 2014;14(3):629-634.
- Chen GD, Gu JL, Qiu J, Chen LZ. Outcomes and risk factors for hepatitis B virus (HBV) reactivation after kidney transplantation in occult HBV carriers. *Transpl Infect Dis*. 2013;15(3):300-305.
- Mahboobi N, Tabatabaei SV, Blum HE, Alavian SM. Renal grafts from anti-hepatitis B core-positive donors: a quantitative review of the literature. *Transpl Infect Dis*. 2012;14(5):445-451.
- Fytily P, Ciesek S, Manns MP, et al. Anti-HBc seroconversion after transplantation of anti-HBc positive nonliver organs to anti-HBc negative recipients. *Transplantation*. 2006;81(5):808-809.
- Pinney SP, Cheema FH, Hammond K, Chen JM, Edwards NM, Mancini D. Acceptable recipient outcomes with the use of hearts from donors with hepatitis-B core antibodies. *J Heart Lung Transplant*. 2005;24(1):34-37.
- Dhillon GS, Levitt J, Mallidi H, et al. Impact of hepatitis B core antibody positive donors in lung and heart-lung transplantation: an analysis of the United Network For Organ Sharing Database. *Transplantation*. 2009;88(6):842-846.
- Hartwig MG, Patel V, Palmer SM, et al. Hepatitis B core antibody positive

- donors as a safe and effective therapeutic option to increase available organs for lung transplantation. *Transplantation*. 2005;80(3):320-325.
31. Shitrit AB, Kramer MR, Bakal I, Morali G, Ben Ari Z, Shitrit D. Lamivudine prophylaxis for hepatitis B virus infection after lung transplantation. *Ann Thorac Surg*. 2006;81(5):1851-1852.
32. Veroux M, Ardita V, Corona D, et al. Kidney transplantation from donors with hepatitis B. *Med Sci Monit*. 2016;22:1427-1434.
33. Asuman Yavuz H, Tekin S, Yuksel Y, et al. Donors with hepatitis B surface antigen positivity. *Transplant Proc*. 2015;47(5):1312-1314.
34. Yap DY, Yung S, Tang CS, et al. Entecavir treatment in kidney transplant recipients infected with hepatitis B. *Clin Transplant*. 2014;28(9):1010-1015.
35. Yap DY, Tang CS, Yung S, Choy BY, Yuen MF, Chan TM. Long-term outcome of renal transplant recipients with chronic hepatitis B infection—impact of antiviral treatments. *Transplantation*. 2010;90(3):325-330.
36. Ridruejo E. Antiviral treatment for chronic hepatitis B in renal transplant patients. *World J Hepatol*. 2015;7(2):189-203.
37. Tuncer M, Tekin S, Yüctin L, Şengül A, Demirbaş A. Hepatitis B surface antigen positivity is not a contraindication for living kidney donation. *Transplant Proc*. 2012;44(6):1628-1629.
38. Chanchaoenthana W, Townamchai N, Pongpirul K, et al. The outcomes of kidney transplantation in hepatitis B surface antigen (HBsAg)-negative recipients receiving graft from HBsAg-positive donors: a retrospective, propensity score-matched study. *Am J Transplant*. 2014;14(12):2814-2820.
39. Loomba R, Liang TJ. Hepatitis B reactivation associated with immune suppressive and biological modifier therapies: current concepts, management strategies, and future directions. *Gastroenterology*. 2017;152(6):1297-1309.