

# ADVANCES IN HEPATOLOGY

Current Developments in the Treatment of Hepatitis and Hepatobiliary Disease

Section Editor: Eugene R. Schiff, MD

## Beta-Catenin Staining of Hepatocellular Adenomas



Monica T. Garcia-Buitrago, MD  
 Professor of Clinical Pathology  
 Director of Gastrointestinal Pathology Service and Fellowship  
 University of Miami Miller School of Medicine  
 Miami, Florida

**G&H** How common are hepatocellular adenomas in the general population overall and among the various types of benign liver tumors?

**MG-B** Hepatocellular adenomas have an estimated incidence of approximately 3 to 4 per 100,000 women. Among benign tumors of the liver, hepatocellular adenomas are the third most common tumors, with the most common being hemangiomas, followed by focal nodular hyperplasia. Hepatocellular adenomas usually occur in female patients of childbearing age who are taking oral contraceptives with high doses of estrogen, and less often in patients taking anabolic steroids or androgenic steroids. Obesity and metabolic syndrome increase the risk of the development and progression of hepatocellular adenomas.

**G&H** How does a hepatocellular adenoma differ from other benign tumors, such as hemangiomas, in terms of features?

**MG-B** A hemangioma is a benign mesenchymal tumor that is composed of varying-sized vascular spaces that are lined by flat endothelial cells. Hemangiomas are often surrounded by a thin capsule and show a spongy red-brown cut surface. In contrast, a hepatocellular adenoma is an epithelial tumor that consists of sheets of hepatocytes with abnormal architecture, no normal portal tracts or bile ducts, and abnormal thick unpaired arteries. Hepatocellular adenomas usually present as solitary masses; however, up to 20% of patients have multiple tumors. These tumors are tan in color, show a fleshy cut surface, and usually have a fibrous capsule. The absence of a capsule may predispose patients to develop intrahepatic or extrahepatic hemorrhage.

**G&H** What is the pathophysiology of these tumors?

**MG-B** Hepatocellular adenomas are monoclonal tumors that probably develop from an interaction between environmental factors such as oral contraceptives, androgens, steatosis, and genetic mutations. These tumors have been classified into 5 different types based upon their molecular signatures: hepatocyte nuclear factor-1 alpha (*HNF1A*)-mutated hepatocellular adenomas, beta-catenin 1 (*CTNNB1*) gene-mutated hepatocellular adenomas, interleukin-6 signal transducer gene-mutated or inflammatory/telangiectatic hepatocellular adenomas, unclassified hepatocellular adenomas, and the recently described sonic hedgehog-activated hepatocellular adenomas.

**G&H** How should hepatocellular adenomas be monitored?

**MG-B** Hepatocellular adenomas should be followed with yearly imaging studies (computed tomography [CT] or magnetic resonance imaging) and frequent alpha-fetoprotein (AFP) quantification. Imaging studies are performed to establish the growth pattern of the tumor and to detect any increase in the size of the tumor, which should alert the clinician to the possibility of major complications such as intrahepatic bleeding or malignant transformation. Hepatocellular adenomas that measure less than 5 cm can be managed conservatively, as they rarely rupture or undergo malignant transformation; however, some of these cases have been reported to develop carcinoma despite their size. Thus, continuous follow-up of these tumors is very important. In hepatocellular adenomas larger than 5 cm, surgical or nonsurgical intervention is

**Table.** Hepatocellular Adenoma Subtypes, Molecular Signatures, and Immunohistochemistries

	Hepatocyte Nuclear Factor-1 Alpha–Mutated Hepatocellular Adenomas (35%)	Beta-Catenin–Mutated Hepatocellular Adenomas (10%-15%)	Inflammatory/Telangiectatic Hepatocellular Adenomas (35%-45%)	Sonic Hedgehog–Activated Hepatocellular Adenomas (4%-5%)	Unclassified Hepatocellular Adenomas (7%)
<b>Molecular Signature</b>	<i>HNF1A</i> mutation	<i>CTNNB1</i> mutation exon 7/8: 3%, exon 3: 7%	<i>IL6ST</i> , <i>STAT3</i> , <i>FRK</i> , <i>GNAS</i> , <i>JAK1</i> mutations  <i>CTNNB1</i> exon 7/8: 4%, exon 3: 6%	Sonic hedgehog activation <i>INHBE/GLI1</i> fusion	No mutation  No mRNAs
<b>Beta-Catenin</b>	Negative	Positive	Negative	Negative	Negative
<b>Liver Fatty Acid–Binding Protein</b>	Negative (lost)	Positive (retained)	Positive (retained)	Positive (retained)	Positive (retained)
<b>Glutamine Synthetase</b>	Negative	Positive (weak/diffuse)	Negative/focal positive	Negative	Negative
<b>C-Reactive Protein</b>	Negative	Negative	Positive	Negative	Negative
<b>Serum Amyloid A</b>	Negative	Negative	Positive	Negative	Negative

mRNAs, messenger RNAs.

recommended. Oral contraceptives, anabolic steroids, and androgens should be discontinued in these patients.

In addition, an initial biopsy is helpful to confirm the diagnosis of hepatocellular adenoma and to subclassify the tumor. If the biopsy shows a beta-catenin–mutated hepatocellular adenoma, the patient should be considered for an early referral for liver resection, as malignant transformation occurs more frequently in this subtype.

#### G&H How often do hepatocellular adenomas undergo malignant transformation?

**MG-B** The risk of malignant transformation has been evaluated in different studies, ranging from 13.0% in a small series to 4.2% in a recent systematic review. In the latter publication, only 4.4% of these malignant transformations occurred in tumors that measured less than 5 cm in diameter.

#### G&H What are the risk factors for malignant transformation?

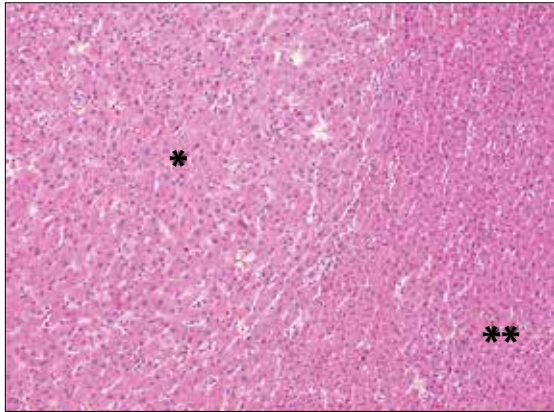
**MG-B** Of all the hepatocellular adenomas, the beta-catenin–mutated subtype carries the highest risk for malignant transformation. This subtype represents approximately 10% to 15% of hepatocellular adenomas and affects both sexes, although it is more commonly seen in men. Additional important risk factors for malignant

transformation of hepatocellular adenomas include male sex, glycogen storage disease, use of anabolic steroids, androgen therapy, and tumors larger than 5 cm in their largest dimension.

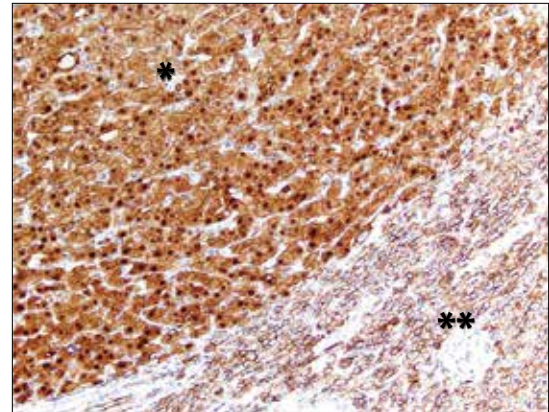
If a biopsy confirms the presence of a beta-catenin–mutated hepatocellular adenoma, follow-up of the patient should be based on the guidelines for hepatocellular carcinoma.

#### G&H Why is it important to try to identify which of these tumors will become malignant?

**MG-B** It is important to identify patients who have hepatocellular adenomas with higher risk of malignancy, as these patients should undergo tumor resection. In contrast, patients without risk of malignancy will require only clinical and imaging studies in their follow-up. Being able to differentiate between these 2 groups of patients allows for the avoidance of unnecessary liver resections and the associated operative risks in patients with hepatocellular adenomas with low risk of complications or malignant transformation. Even though hepatocellular adenomas are benign tumors, management should be based upon the presence or absence of clinical risk factors, size progression on consecutive imaging studies, and histologic examination with beta-catenin assessment. The management of beta-catenin–mutated tumors differs from the management of other subtypes of hepatocellular adenomas.



**Figure 1.** A hematoxylin and eosin stain (40× magnification) showing a beta-catenin–mutated hepatocellular adenoma (\*) and nontumoral liver tissue (\*\*).



**Figure 2.** A beta-catenin immunostain (40× magnification) showing nuclear and cytoplasmic positivity in a beta-catenin–mutated hepatocellular adenoma (\*) but only membranous staining in nontumoral tissue (\*\*).

### G&H Which methods can be used to determine which tumors are more likely to undergo malignant transformation?

**MG-B** Liver biopsy remains the sole option to detect which hepatocellular adenomas show a beta-catenin mutation and, therefore, are more likely to undergo malignant transformation. Currently, in our institution, my colleagues and I evaluate these liver biopsies by using immunostains for beta-catenin, liver fatty acid-binding protein (LFABP), serum amyloid A, C-reactive protein, and glutamine synthetase. These immunostains help to confirm the diagnosis and to subclassify hepatocellular adenomas. For example, *HNF1A*-mutated hepatocellular adenomas are negative for the LFABP immunostain, beta-catenin–mutated hepatocellular adenomas show positive nuclear and cytoplasmic staining for the beta-catenin immunostain, and inflammatory/telangiectatic hepatocellular adenomas are positive for the serum amyloid A and C-reactive protein immunostains (Table).

Additionally, molecular studies can be used to evaluate hepatocellular adenoma–specific genes, including *HNF1A*, *CTNNB1* (all exons), *IL6ST*, *STAT3*, *GNAS*, *FRK*, and *JAK1* using DNA next-generation sequencing.

Activation of beta-catenin occurs due to missense mutation, small in-frame insertion or deletions in exons 3, 7, and 8 of the *CTNNB1* gene, which causes cytoplasmic and nuclear accumulation of beta-catenin. The alteration of exon 3 is the only mutation that has been associated with a higher risk of malignant progression.

Beta-catenin is usually present in normal tissue; normal hepatocytes show membranous staining by immunohistochemistry. The hepatocellular adenomas with nuclear staining for the beta-catenin immunostain are the

tumors that have a higher risk of undergoing malignant transformation (Figures 1 and 2).

Several studies have confirmed that the subclassification of hepatocellular adenomas with immunohistochemistry is very useful and an accurate method for differentiating which tumors may show malignant transformation. Hepatocellular carcinoma associated with adenoma has been reported in 46% of beta-catenin–mutated tumors, whereas malignancy has been rarely reported in *HNF1A*-mutated tumors (7%), unclassified tumors (13%), or inflammatory/telangiectatic tumors (very rare).

### G&H What are the benefits and advantages of beta-catenin staining?

**MG-B** In comparison to molecular studies, and similar to other immunohistochemical stains, the beta-catenin immunostain is a nonexpensive method used as a diagnostic marker of the beta-catenin mutation. A beta-catenin–mutated hepatocellular adenoma exhibits distinct nuclear positivity with a beta-catenin immunostain that is easier to interpret than other types of staining, such as cytoplasmic staining alone, which may be misinterpreted with uniform “blush” heterogeneous staining.

### G&H What are the limitations of using immunostains, including the beta-catenin immunostain, in hepatocellular adenomas?

**MG-B** In general, the usefulness of immunohistochemistry depends on the size and quality of the tissue biopsy examined. Because focal beta-catenin positivity has been described in few beta-catenin–mutated hepatocellular adenomas, small tissue biopsies might be insufficient and

may demonstrate a false-negative result. It is important to note that benign fibroblasts encountered in liver biopsies and other tumors, such as colonic carcinomas, papillary thyroid carcinomas, and endometrial adenocarcinomas, stain positive for beta-catenin. Thus, correlation with histomorphologic features is required.

Another limitation is that these immunostains are not available in all laboratories for routine clinical practice.

Molecular studies are a more definitive method of subclassifying hepatocellular adenomas. However, this methodology is also not widely available and should be done as the last resort.

### G&H Can beta-catenin staining be used in all patients with hepatocellular adenomas?

**MG-B** At our institution, beta-catenin immunostains are ordered in all liver biopsies that morphologically show definitive or suspicious features of hepatocellular adenomas, as part of tumor subclassification, along with the 4 other immunostains previously mentioned. There are no contraindications to ordering the panel of immunostains in hepatocellular adenoma biopsies in any patients or situations.

### G&H If malignant transformation occurs, what are the usual next steps for management?

**MG-B** Patients are deemed to have malignant transformation of a previously diagnosed hepatocellular adenoma when they show an elevation of AFP in serum and meet the criteria for Liver Imaging Reporting and Data System categories 4 or 5 by showing characteristic or suspicious features of hepatocellular carcinoma in imaging studies. Malignant features include tumor enhancement on arterial phase with subsequent washout on portal venous phase by contrast-enhanced CT. The pathology features include positive nuclear beta-catenin staining and positive hepatocellular carcinoma immunostains, such as glypican 3 and heat shock protein 70. These patients should be scheduled for surgical or nonsurgical intervention (ie, transarterial chemoembolization, radiofrequency ablation) regardless of tumor size. Hepatocellular carcinoma arising from a hepatocellular adenoma can be resected with a segmentectomy or partial lobectomy, or, in select cases, liver transplantation can be performed.

### G&H What are the next steps in research?

**MG-B** One of the next steps is to better categorize the hepatocellular adenomas that are currently considered to be unclassified, which account for 7% of hepatocellular adenomas. The molecular signature of these tumors is unknown, as is how they will behave and whether they carry any risk of malignant transformation based on their gene expression. As mentioned before, a fifth subtype of hepatocellular adenoma was recently recognized, the sonic hedgehog-activated tumor, which accounts for 4% to 5% of all hepatocellular adenomas and half of the tumors that were previously considered to be unclassified. Sonic hedgehog-activated hepatocellular adenomas show a somatic fusion between inhibin beta E subunit (*INHBE*) and *GLI1*, leading to overexpression of *GLI1*. To date, these tumors have been associated only with a higher risk of bleeding. New molecular techniques will help us to better understand the signatures of the different histologic subtypes and the mechanism of malignant transformation.

*Dr Garcia-Buitrago has no relevant conflicts of interest to disclose.*

### Suggested Reading

Bioulac-Sage P, Laumonier H, Couchy G, et al. Hepatocellular adenoma management and phenotypic classification: the Bordeaux experience. *Hepatology*. 2009;50(2):481-489.

Farges O, Dokmak S. Malignant transformation of liver adenoma: an analysis of the literature. *Dig Surg*. 2010;27(1):32-38.

Margolske E, Bao F, de Gonzalez AK, et al. Hepatocellular adenoma classification: a comparative evaluation of immunohistochemistry and targeted mutational analysis. *Diagn Pathol*. 2016;11:27.

Nault JC, Bioulac-Sage P, Zucman-Rossi J. Hepatocellular benign tumors—from molecular classification to personalized clinical care. *Gastroenterology*. 2013;144(5):888-902.

Nault JC, Couchy G, Balabaud C, et al. Molecular classification of hepatocellular adenoma associates with risk factors, bleeding, and malignant transformation. *Gastroenterology*. 2017;152(4):880-894.e6.

Shafizadeh N, Kakar S. Diagnosis of well-differentiated hepatocellular lesions: role of immunohistochemistry and other ancillary techniques. *Adv Anat Pathol*. 2011;18(6):438-445.

Stoot JH, Coelen RJ, De Jong MC, Dejong CH. Malignant transformation of hepatocellular adenomas into hepatocellular carcinomas: a systematic review including more than 1600 adenoma cases. *HPB (Oxford)*. 2010;12(8):509-522.

Vijay A, Elaffandi A, Khalaf H. Hepatocellular adenoma: an update. *World J Hepatol*. 2015;7(25):2603-2609.

Zucman-Rossi J, Jeannot E, Nhieu JT, et al. Genotype-phenotype correlation in hepatocellular adenoma: new classification and relationship with HCC. *Hepatology*. 2006;43(3):515-524.