

# ADVANCES IN ENDOSCOPY

Current Developments in Diagnostic and Therapeutic Endoscopy

Section Editor: John Baillie, MB ChB, FRCP

## Pancreatic Pseudocyst Drainage Using Lumen-Apposing Metal Stents



Michel Kahaleh, MD, AGAF, FACC, FASGE  
 Chief of Endoscopy  
 Division of Gastroenterology and Hepatology  
 Weill Cornell Medical College  
 New York, New York

### G&H What is the standard approach to draining pancreatic fluid collections via endoscopic means?

**MK** Currently, the most common approach is with endoscopic ultrasound (EUS) guidance. Using EUS with a large working channel, the endoscopist can puncture and then drain the fluid collection after checking local vasculature with Doppler ultrasound. The drainage will depend on the type of fluid collection. For example, if the patient has a simple pseudocyst, the endoscopist could place a single 10-French plastic stent. However, if the patient has an infected fluid collection, typically the endoscopist would place many plastic stents or consider lumen-apposing metal stents (LAMS; Figure 1).

### G&H What training is needed to drain pancreatic fluid collections?

**MK** Draining pancreatic fluid collections is a complex procedure that is not normally taught in a general gastrointestinal (GI) fellowship. This procedure is reserved for advanced endoscopists who work in tertiary or quaternary care centers. Most interventional or advanced endoscopists now receive a fourth year of training after becoming board-certified in gastroenterology. In the training program at Weill Cornell Medical College, I typically start teaching this technique during the midyear of advanced fellow training. Teaching this technique requires 1-on-1 supervision for every step of the procedure.

### G&H What are the advantages of using EUS for drainage vs any other technique?

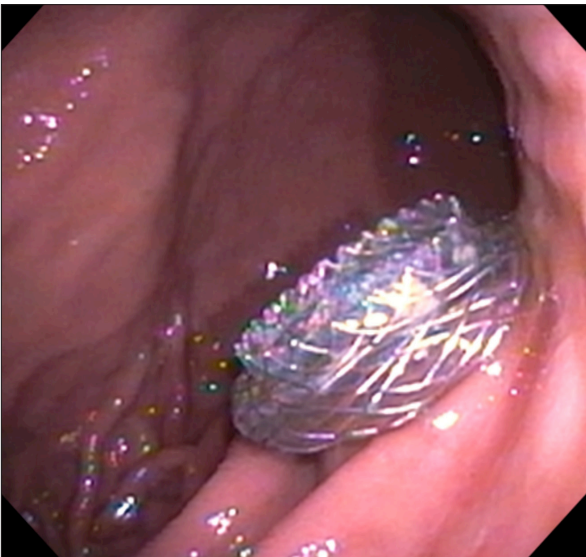
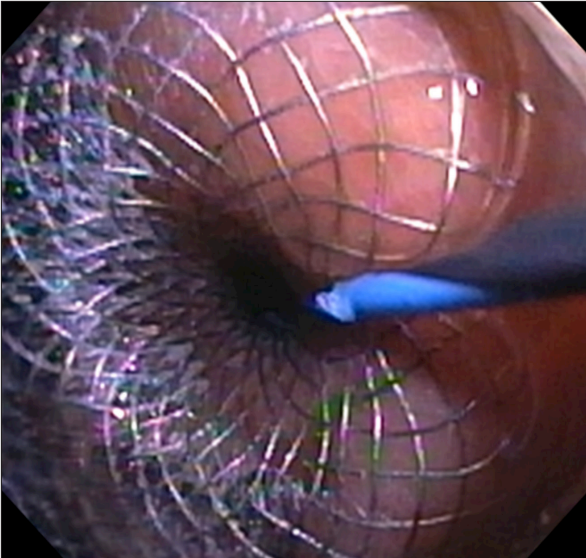
**MK** EUS is recommended for conventional drainage and when the patient does not have a large bulge into the GI lumen. The technique allows the endoscopist to access the fluid collections that are not pushing against the wall of the stomach or the small bowel. EUS can also help the endoscopist to avoid vessels, and, overall, it provides a safer window into the pancreatic fluid collection. The main concern with endoscopy is encountering a vessel interposed between the lumen of the stomach and the fluid collection. Therefore, the majority of pancreatic fluid collections today are drained with EUS guidance.

### G&H Are there any limitations or disadvantages associated with this procedure?

**MK** When a pancreatic fluid collection is drained using a conventional technique (ie, without EUS), the endoscopist aims for the bulge in a perpendicular fashion using fluoroscopy (Figure 2). The EUS puncture tends to be more tangential than perpendicular, which can be a little uncomfortable when the stent is being placed. However, that is becoming less of an issue because EUS can be used to deploy LAMS, creating an anastomosis between the fluid collection and the stomach.

### G&H Is there a risk of stent migration with LAMS?

**MK** The risk of stent migration is very limited with LAMS because they have 2 large flanges at the end that reduce the chance of migration. One flange is inside the fluid collection, and the other flange is in the stomach or the small intestine. There is a large channel in between



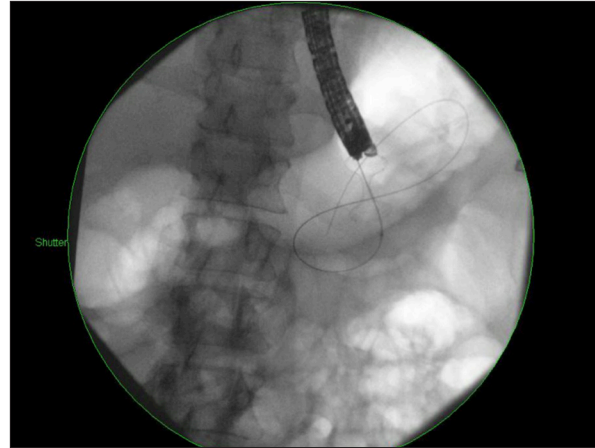
**Figure 1.** A lumen-apposing metal stent is deployed into a pancreatic pseudocyst.

the flanges that creates the connection between the fluid collection and the stomach.

**G&H** Are there any adverse events related to this procedure?

**MK** Although the stents themselves do not present a major concern once they are placed, the drainage procedure can lead to a perforation or leakage. Thus, it is necessary to reserve this procedure for trained and advanced endoscopists.

Bleeding is also always a risk when performing pancreatic fluid collection drainage. These episodes of bleeding are related to vessels being decompressed by the drainage of the collection or a vessel that was in the trajectory of the needle. Endoscopists should use EUS to decrease



**Figure 2.** Using fluoroscopy, an endoscopist can drain a pancreatic fluid collection by aiming for the bulge in a perpendicular fashion.

the risk of bleeding. To treat major bleeding if it occurs, endoscopists can balloon tamponade the bleeding vessel during the procedure and finish deploying the stent. Delayed bleeding is typically dealt with by sending the patient for embolization using interventional radiology.

**G&H** What is the difference between standard covered self-expanding metal stents and LAMS?

**MK** Standard covered self-expanding metal stents (CSEMS) are covered biliary metal stents. CSEMS were designed for bile duct drainage but have been used for fluid collection drainage. However, they do not have antimigratory features, which limits their utility in this setting.

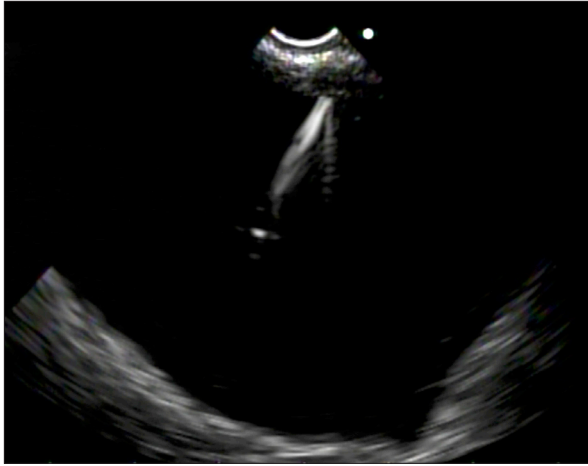
In contrast, LAMS are very short in length and were designed for drainage of pancreatic fluid collections. LAMS also have large flanges on each end and, as their name suggests, appose the fluid collection to the stomach or duodenum.

**G&H** What are the advantages of LAMS?

**MK** LAMS are easier to place. They have a large diameter of 10 to 15 mm, which offers better drainage. With LAMS, an endoscopist can enter the collection via the stent and clean its content from debris. That is a feature that biliary metal stents do not allow, and it is a benefit that endoscopists should take advantage of.

**G&H** Does placing LAMS require training?

**MK** Yes, endoscopists need specific training to familiarize themselves with the device and the procedure. They need not only to learn the technique of draining the pseudocyst during an advanced endoscopy fellowship,



**Figure 3.** An endoscopic ultrasound image of a cystgastrostomy fine-needle aspiration.

but they also need to understand the mechanism and the deployment of LAMS.

### G&H What are the benefits of endoscopic drainage compared with surgical cystgastrostomy?

**MK** Surgical drainage of pancreatic fluid collections is much more invasive and requires going through the abdomen of the patient. That means surgical cystgastrostomy not only leaves scars, but it increases the risk of infection and complication in the peritoneum as well (Figure 3). Endoscopic drainage is performed completely internally, which allows the procedure to be minimally invasive. This leads to decreased chances of accessing the peritoneum and developing an infection.

A randomized controlled trial was performed recently that assessed surgical vs endoscopic drainage for pancreatic pseudocysts and showed the superiority of endoscopy in terms of shorter hospital stays, better physical and mental health of patients, and lower cost. The gold standard treatment for pancreatic fluid collection drainage is now endoscopy.

### G&H How long can LAMS be left in place before removal?

**MK** LAMS can be left in place between 1 to 3 months before being removed. Most pancreatic fluid collections improve within a month, and typically by 2 to 3 months, the collection has resolved.

### G&H Are there any patients in whom this technique should be avoided?

**MK** Patients who do not have an organized fluid collection should not undergo pancreatic fluid collection drainage. Those patients would benefit the most from enteral feeding in the hope that the collection will become organized.

### G&H Should LAMS be used in conjunction with any other treatments?

**MK** Endoscopists should assess the pancreatic duct via endoscopic retrograde cholangiopancreatography (ERCP) to treat any disruption or stenosis that is preventing the fluid collection from resolving. Leaks and stenosis of the pancreatic duct should be repaired via ERCP and stenting in order to permit the collection to drain completely. Failure of transmural drainage is associated with persistent pancreatic duct disruption or blockage.

### G&H What is the priority for research in this field?

**MK** There is a need to focus on increasing the size and efficacy of LAMS. The bigger these stents are, the more efficient treatment and drainage would be. Stent diameters of 15 mm are useful, but 20- to 25-mm stents would be even better.

Another focus is related to the different types of fluid collections. The literature shows that LAMS work with pancreatic fluid collections, but it would be useful to have a study looking specifically at pancreatic necrosis using LAMS because data are still very limited in this area.

*Dr Kahaleh is a consultant for Boston Scientific. He has also received research support from Gore Medical, EMcision, Pinnacle, Cook Group, and Olympus.*

### Suggested Reading

- Baron TH, Harewood GC, Morgan DE, Yates MR. Outcome differences after endoscopic drainage of pancreatic necrosis, acute pancreatic pseudocysts, and chronic pancreatic pseudocysts. *Gastrointest Endosc.* 2002;56(1):7-17.
- Gornals JB, De la Serna-Higuera C, Sánchez-Yague A, Loras C, Sánchez-Cantos AM, Pérez-Miranda M. Endosonography-guided drainage of pancreatic fluid collections with a novel lumen-apposing stent. *Surg Endosc.* 2013;27(4):1428-1434.
- Park DH, Lee SS, Moon SH, et al. Endoscopic ultrasound-guided versus conventional transmural drainage for pancreatic pseudocysts: a prospective randomized trial. *Endoscopy.* 2009;41(10):842-848.
- Sadik R, Kalaitzakis E, Thune A, Hansen J, Jönson C. EUS-guided drainage is more successful in pancreatic pseudocysts compared with abscesses. *World J Gastroenterol.* 2011;17(4):499-505.
- Shah RJ, Shah JN, Waxman I, et al. Safety and efficacy of endoscopic ultrasound-guided drainage of pancreatic fluid collections with lumen-apposing covered self-expanding metal stents. *Clin Gastroenterol Hepatol.* 2015;13(4):747-752.
- Varadarajulu S, Bang JY, Sutton BS, Trevino JM, Christein JD, Wilcox CM. Equal efficacy of endoscopic and surgical cystgastrostomy for pancreatic pseudocyst drainage in a randomized trial. *Gastroenterology.* 2013;145(3):583-590.e1.