

# ADVANCES IN HEPATOLOGY

Current Developments in the Treatment of Hepatitis and Hepatobiliary Disease

Section Editor: Eugene R. Schiff, MD

## Early Detection of Hepatocellular Carcinoma Through Surveillance Using Biomarkers



Robert G. Gish, MD  
Robert G. Gish Consultants, LLC  
San Diego, California

### G&H What is the prevalence of hepatocellular carcinoma?

**RG** Globally, between 600,000 and 1 million new cases of hepatocellular carcinoma (HCC) are diagnosed each year. In the United States, about 26,000 to 27,000 cases of liver cancer are diagnosed each year, and that number is increasing year after year. In fact, HCC is one of the few cancers that is increasing in incidence in the United States. The increase is due to the “maturation” of persons infected with hepatitis C virus (HCV) and hepatitis B virus (HBV) infection and also the increasing prevalence of fatty liver disease, which is emerging as a leading cause of cirrhosis.

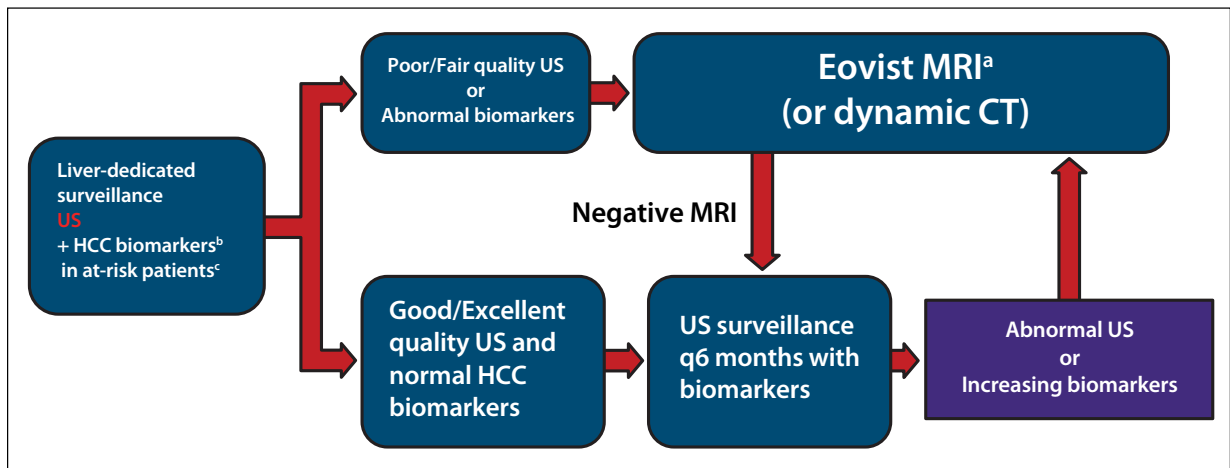
### G&H Historically, how has liver cancer been diagnosed, and how are diagnostic protocols changing?

**RG** The diagnosis of liver cancer is most commonly made by imaging. Historically, measurement of serum alpha-fetoprotein (AFP) levels has been used to “diagnose” liver cancer or lead to imaging of the liver that results in a diagnosis of liver cancer with the occasional use of tumor biopsy for confirmation. The practice of measuring serum AFP levels to diagnose HCC, however, is on the wane because the findings, in and of themselves, lack sensitivity and specificity. In fact, in 2009, the American Association for the Study of Liver Diseases (AASLD) dropped AFP level analysis from its surveillance guidelines on the diagnosis of liver cancer. This action resulted in a resounding series of complaints from the hepatology community, with many practitioners arguing that the monitoring of

AFP levels is useful in guiding imaging and management decisions in patients at risk for HCC. Included in the argument was that reliance on certain imaging techniques only, instead of AFP analysis combined with imaging, was inefficient for surveillance purposes. It was pointed out that, for surveillance, computed tomography (CT) scans are expensive and involve radiation, and magnetic resonance imaging (MRI) is also expensive and requires contrast media that can be associated with adverse effects, although this is rare. As for ultrasound, it is the only recommended and cost-effective imaging modality appropriate for HCC surveillance, although its sensitivity is relatively low and variable, especially in obese patients. It is also not appropriate for diagnosis of liver cancer—for which CT scans and MRI are standard.

Because of complaints about the exclusion of biomarkers in the 2009 AASLD guidelines, new guidelines are expected in which AFP analysis will again be recommended and parallel the advocacy for AFP utilization that is seen in the Asia-Pacific Association for the Study of the Liver, the National Comprehensive Cancer Network, and the US Veterans Administration guidelines.

Whereas the sensitivity of AFP analysis used in conjunction with ultrasound to detect early-stage HCC has ranged from about 40% to 65%, the combination use of newer biomarkers, the *Lens culinaris* agglutinin-reactive fraction of AFP (AFP-L3) and des-gamma-carboxy prothrombin (DCP) plus ultrasound, provides a sensitivity of nearly 85% and a specificity of nearly 95%. More importantly, these biomarkers are risk markers, as per the package insert and product information approved by the US Food and Drug Administration (FDA).



**Figure.** A proposed liver ultrasound algorithm for surveillance of hepatocellular carcinoma.

<sup>a</sup>See LI-RADS at <http://www.acr.org/Quality-Safety/Resources/LIRADS>.

<sup>b</sup>Blood tests AFP-L3/DCP (HCC serum biomarkers).

<sup>c</sup>AASLD Guidelines 2009.

AASLD, American Association for the Study of Liver Diseases; AFP, alpha-fetoprotein; CT, computed tomography; DCP, des-gamma-carboxy prothrombin; HCC, hepatocellular carcinoma; LI-RADS, Liver Imaging Reporting and Data System; MRI, magnetic resonance imaging; US, ultrasound.

## G&H How do AFP-L3 and DCP improve upon AFP?

**RG** AFP is a protein normally produced by the yolk sac and the liver during fetal development and by regenerating hepatocytes. AFP-L3, a fucosylated isoform of AFP, binds to the lectin *Lens culinaris* agglutinin and is increased in patients with HCC. The ratio of AFP-L3 to total AFP is the HCC biomarker. Patients with an AFP-L3 level of 10% or greater are at increased risk for development of HCC.

DCP is an immature form of prothrombin. Normal hepatocytes posttranslationally carboxylate prothrombin precursors before secretion. Because HCC cells have a carboxylation defect, secreted noncarboxylated prothrombin precursors (ie, DCP) can signal HCC activity and, thus, act as biomarkers of HCC risk.

## G&H What is the real utility for liver cancer biomarkers today, and how have things changed since 2009?

**RG** The first and main utility of biomarkers is predicting future risk of liver cancer. An elevated biomarker that appears to be rising suggests risk of liver cancer in the near term even if imaging is negative. Thus, the FDA has approved AFP-L3 and DCP for use in determining the risk of liver cancer. Note that the FDA did not approve these biomarkers to diagnose liver cancer but rather to gauge the possibility of developing HCC. With this comes the responsibility in the hepatology and oncology communities to recognize the risks of HCC and use the approved risk markers efficiently and appropriately in combination with the patient's clinical scenario.

Although AFP-L3 and DCP are now FDA-approved for use as risk markers, AFP was never FDA-approved as a stand-alone test for analysis related to the diagnosis or risk of liver cancer, although it has long been used in that context. Its use is now FDA-approved in combination with AFP-L3. In following FDA guidelines and approved uses, clinicians could either use DCP and AFP-L3 in combination or AFP-L3 and AFP and/or DCP in combination.

## G&H How are AFP, AFP-L3, and DCP specifically used in the clinical setting?

**RG** Screening for liver disease is the first step, including surveillance, or ongoing testing, of patients with HBV, particularly Asian men who are older than 40 years, women older than 50 years with chronic HBV infection, and patients with cirrhosis or HCV infection with cirrhosis. In my opinion, surveillance protocols should include measurement of these FDA-approved biomarkers and ultrasound imaging.

Besides being used to identify patients at risk for progression to HCC, biomarkers are used to identify candidates for liver transplantation. Let us say that a patient who has liver cancer is found to have elevated AFP, AFP-L3, or DCP or some combination of these biomarkers. The higher the level of a detected biomarker and the more biomarkers that are detected, the higher the risk of cancer recurrence after an intervention such as resection or liver transplantation. Presently, United Network for Organ Sharing (UNOS) guidelines require that serum AFP levels not exceed 500 ng/mL, as UNOS believes that

AFP levels that exceed 500 ng/mL predict a very high risk of cancer recurrence and graft loss or patient death from recurrent tumor. The tumor should be treated and an effort made to decrease or normalize AFP levels before a liver transplant is considered. The UNOS standard is meant to optimize organ utilization.

Biomarkers also provide information on the risk of developing metastatic disease and the presence or development of poorly differentiated tumors. The higher the biomarker levels and the greater the number of biomarkers that are positive, the more likely it is that a patient is going to have a poorly differentiated tumor. The more poorly differentiated the tumor, the more likely it is that the patient is going to have cancer recurrence, metastatic disease, or vascular invasion.

These biomarkers should be used in combination, not as stand-alones, and should be used to help guide use of imaging. In this way, their use can be potentially cost-saving. Let us say that I have a patient who has a body mass index of 35 kg/m<sup>2</sup>, who is negative for all 3 biomarkers, and whose ultrasound quality is good. I am going to be much less likely to order an MRI or CT scan. On the other hand, if I have an obese patient who has a moderate-quality ultrasound and rising DCP and AFP-L3 levels, I will be prompted to order an MRI even if the ultrasound findings are normal or negative.

Let us take another clinical scenario. Say I have a patient with HCV infection, fatty liver disease, and borderline cirrhosis. If the patient's HCV infection is cured, but the levels of the HCC biomarker(s) remain elevated, I am going to perform regular, long-term surveillance on this patient and potentially use advanced imaging such as MRI. The Figure shows a proposed algorithm for surveillance of HCC.

*Dr Gish has acted as a consultant for and is a member of the Speakers Bureau of Wako Diagnostics.*

### Suggested Reading

Lok AS, Sterling RK, Everhart JE, et al. Des-gamma-carboxy prothrombin and alpha-fetoprotein as biomarkers for the early detection of hepatocellular carcinoma. *Gastroenterology*. 2010;138(2):493-502.

Tamura Y, Suda T, Arai S, et al. Value of highly sensitive fucosylated fraction of alpha-fetoprotein for prediction of hepatocellular carcinoma recurrence after curative treatment. *Dig Dis Sci*. 2013;58(8):2406-2412.

Toyoda H, Kumada T, Kiriya S, et al. Prognostic significance of simultaneous measurement of three tumor markers in patients with hepatocellular carcinoma. *Clin Gastroenterol Hepatol*. 2006;4(1):111-117.

Volk ML, Hernandez JC, Su GL, Lok AS, Marrero JA. Risk factors for hepatocellular carcinoma may impair the performance of biomarkers: a comparison of AFP, DCP, and AFP-L3. *Cancer Biomark*. 2007;3(2):79-87.