

ADVANCES IN ENDOSCOPY

Current Developments in Diagnostic and Therapeutic Endoscopy

Section Editor: John Baillie, MB ChB, FRCP

Difficult Endoscopic Retrograde Cholangiopancreatography



John Baillie, MB ChB, FRCP
Director of Medical Gastroenterology
Carteret General Hospital
Morehead City, North Carolina

G&H What constitutes a difficult endoscopic retrograde cholangiopancreatography?

JB Most endoscopists who are asked this question would immediately think of anatomic problems that limit or prevent access to the main duodenal papilla for cannulation, such as prior upper gastrointestinal surgery (eg, Billroth II gastrectomy, Roux-en-Y biliary diversion, or gastric bypass procedures) or gastric outlet obstruction (Figure 1). However, the difficulty of an endoscopic retrograde cholangiopancreatography (ERCP) can begin before the endoscope is even passed; factors that increase the risks of sedation and endoscopy add to the difficulty of ERCP.

G&H Could you give a few specific examples of difficult ERCPs?

JB With the explosion of obesity in the United States, body habitus must be considered when evaluating patients for ERCP. Morbidly obese persons are harder to sedate with standard intravenous agents (moderate sedation), more likely to suffer from sleep apnea, and more difficult to resuscitate in an emergency. Increasingly, ERCP is being performed under monitored anesthesia care or full general anesthesia, and this is especially important in obese patients. The standard semiprone (almost face-down) position typically used for ERCP adds to the difficulty of accessing the airway in the event of respiratory depression or arrest in these patients. For this reason, anesthesia providers may request that the procedure be performed in the supine position, which is technically more demanding. Patients under anesthesia are usually immobilized by tape or straps attached to the fluoroscopy table, making subsequent repositioning

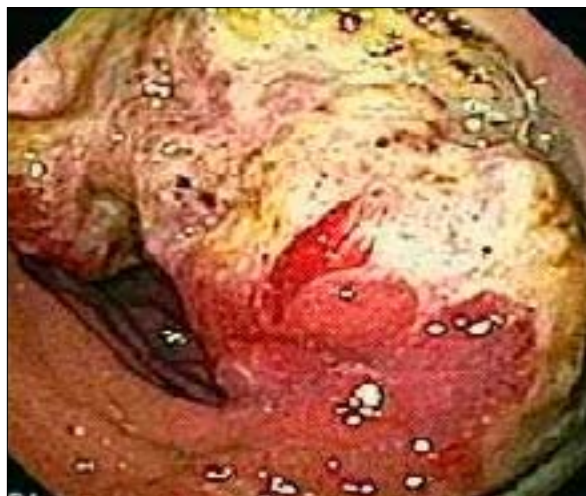

Figure 1. A duodenal tumor obstructing access to the main duodenal papilla for endoscopic retrograde cholangiopancreatography.

more difficult (eg, rolling up into the left lateral position to facilitate intubation of the pylorus).

ERCP can also be made more difficult by patient agitation, resulting in coughing, retching, and exaggerated respiratory excursion and peristalsis, which essentially create a moving target for the endoscopist. Effective sedation (usually delivered by an anesthesia provider), analgesia (when required), and motility control with intravenous glucagon take care of most of these problems.

In addition, therapeutic anticoagulation that has not been reversed—wholly or partially—before the procedure limits therapeutic options, as standard sphincterotomy can be complicated by immediate or delayed bleeding. Alternative approaches must be considered—

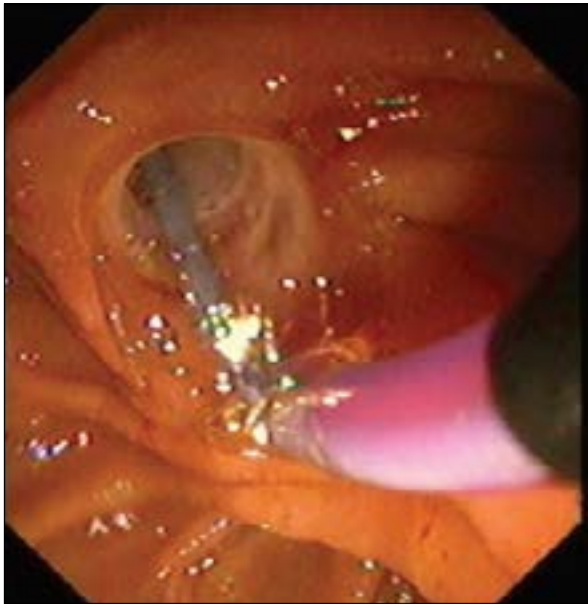


Figure 2. Balloon dilation of the duodenal papilla (balloon sphincteroplasty).

such as balloon dilation of the papilla (balloon sphincteroplasty; Figure 2) and cannulation of the bile duct using a basket catheter—to retrieve small stones. When stones cannot be removed through the intact papilla in this setting, temporary biliary stenting will decompress an obstructed bile duct and allow sepsis and jaundice to resolve without cutting the sphincter. Once the patient's coagulopathy has resolved, or has been completely corrected, standard sphincterotomy can be performed with minimal risk of bleeding.

Also, ERCP in the setting of severe acute pancreatitis can be technically demanding due to loss of mucosal features in the duodenum caused by edema from the inflammatory process. ERCP in the setting of gallstone pancreatitis requires an experienced endoscopist for this reason. Gastric retention of food may also severely limit endoscopic visualization of the pylorus, duodenum, and duodenal papilla.

G&H Does pregnancy increase the risk of a difficult ERCP?

JB Pregnancy was once considered an absolute contraindication to ERCP; endoscopists feared that a complication such as pancreatitis or bleeding could harm the fetus as well as the mother. However, since the first case series of successful, uncomplicated ERCP in pregnancy was published by my colleagues and I in 1990, there has not been a single report of maternal or fetal mortality in this setting. Nevertheless, the use of ionizing radiation must be kept to a minimum when performing ERCP on preg-

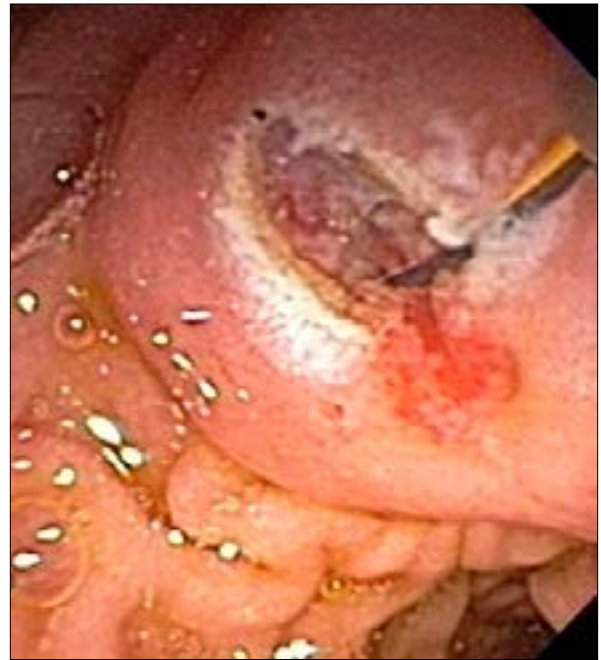

Figure 3. Minor duodenal papillotomy performed over a guidewire.

nant women, and particular care must be taken to shield the fetus using a strategically placed lead apron.

G&H What should an endoscopist do if he or she has trouble finding the duodenal papilla?

JB The most common reason for not being able to identify the duodenal papilla is anatomic rearrangement of the upper gastrointestinal anatomy. An understanding of the new anatomy is the key to success in such cases. Provided that the afferent limb of the gastroenterostomy created as part of a Billroth II gastrectomy is not too long, the papilla can almost always be reached in a retrograde fashion. However, successfully cannulating that papilla will be difficult if the endoscopist does not take into account that the papilla is being viewed upside down compared with standard ERCP, thus altering the axis of the bile duct and the pancreatic duct. The length of the Roux limb in the latest style of gastric bypass (bariatric) surgery may exceed that of the endoscope. A pediatric colonoscope may be long enough to reach the papilla, but standard ERCP accessories (eg, cannulas, baskets, and balloon catheters) are too short to be used. Maneuvers to shorten the distance to the papilla include passing the endoscope through the mature track of a percutaneous endoscopic gastrostomy and laparoscopic-assisted ERCP, in which the tip of the duodenoscope is placed in the lumen of the stomach through a trocar that has been placed there laparoscopically.

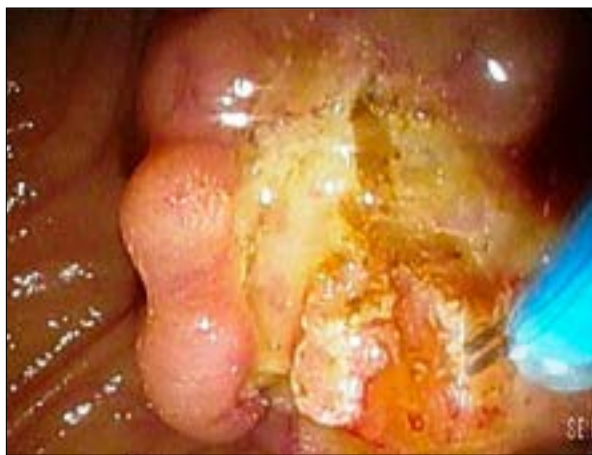

Figure 4. Needle knife incision of a chronically inflamed bile duct to provide access for stone removal.

If the duodenal papilla cannot be identified in a patient with otherwise normal local anatomy, it may be hiding within or in the vicinity of a duodenal diverticulum. Careful inspection of diverticula on the medial wall of the descending duodenum will usually reveal the missing papilla. Cannulating it may present yet another difficulty if the presence of the diverticulum has distorted the axis of the desired duct(s).

When inexperienced endoscopists cannot find the papilla, it is often because they are looking in the wrong place. If the endoscope has unwittingly been advanced into the so-called long position, and not subsequently shortened (usually to around 60 cm from the lips), the papilla may be nowhere to be seen. Novice endoscopists should use fluoroscopy to ensure that the endoscope is positioned correctly.

G&H What are the keys to performing successful cannulation during ERCP?

JB An endoscopist should never poke or otherwise traumatize the duodenal papilla. Gentle manipulation of the papilla with a catheter using appropriate orientation (11 o'clock for the bile duct and 3 o'clock for the pancreatic duct) is the most successful approach for cannulation. Trauma to the papilla from a failed cannulation greatly increases the risk of post-ERCP pancreatitis (PEP). A technique that significantly reduces this risk—although it does not completely abolish it—is guidewire-assisted cannulation, whereby a short length of a soft (hydrophilic) guidewire is advanced beyond the tip of the catheter and used to probe the papilla to reveal the ducts. Deep access to the desired duct allows placement of a plastic stent, which can be used to orient the endoscopist to its

axis for precut papillotomy (usually with a needle knife). Repeated failure to access the main pancreatic duct for pancreatography through the main papilla may be the result of congenital malunion of the dorsal and ventral ducts, causing pancreas divisum. In this condition, the dominant pancreatic duct (the dorsal one) empties through the minor duodenal papilla. Patients with pancreas divisum and recurrent attacks of acute pancreatitis may respond to minor papillotomy (Figure 3), which is usually performed over a guidewire or a small-caliber (eg, 5-French gauge) stent placed deep into the dorsal duct.

Difficult cannulation of the bile duct may result from distortion of the local anatomy by masses, congenital malformations (choledochal cysts), large diverticula, and so on. Difficult cannulation may also result from the bile duct being a very small target. A variety of techniques are available to increase the success of biliary cannulation, including needle-knife papillotomy (NKP).

G&H Is it true that NKP is a dangerous technique?

JB NKP can be dangerous in inexperienced hands and for many years has been blamed unfairly for increasing the risk of PEP. NKP is frequently used as a rescue maneuver after repeated failure to cannulate the duodenal papilla, a common scenario leading to procedure-related pancreatitis. However, it has recently been confirmed that the risk of PEP in this setting is related to the number of failed cannulations before NKP, not to the act of NKP itself. Figure 4 shows needle knife incision of a chronically inflamed and thickened distal bile duct in a patient with recurrent bile duct stone formation (choledocholithiasis).

Dr Baillie has no relevant conflicts of interest to disclose.

Suggested Reading

- Ferreira LE, Baron TH. Comparison of safety and efficacy of ERCP performed with the patient in supine and prone positions. *Gastrointest Endosc*. 2008;67(7):1037-1043.
- Gorospe EC, Oxentenko AS. Preprocedural considerations in gastrointestinal endoscopy. *Mayo Clin Proc*. 2013;88(9):1010-1016.
- Baillie J, Cairns S, Putnam WS, Cotton PB. Endoscopic management of choledocholithiasis during pregnancy. *Surg Gynecol Obstet*. 1990;171(1):1-4.
- Richardson JF, Lee JG, Smith BR, et al. Laparoscopic transgastric endoscopy after Roux-en-Y gastric bypass: case series and review of the literature. *Am Surg*. 2012;78(10):1182-1186.
- Tse F, Yuan Y, Moayyedi P, Leontiadis GI. Guide wire-assisted cannulation for the prevention of post-ERCP pancreatitis: a systematic review and meta-analysis. *Endoscopy*. 2013;45(8):605-618.
- Bailey AA, Bourke MJ, Kaffes AJ, et al. Needle-knife sphincterotomy: factors predicting its use and the relationship with post-ERCP pancreatitis (with videos). *Gastrointest Endosc*. 2010;71(2):266-271.