

Refractory Pancolitis: A Novel Presentation of Idiopathic Myointimal Hyperplasia of Mesenteric Veins

Jason Korenblit, MD, MBA¹
 Ashlie Burkart, MD, CM²
 Robert Frankel, BS⁴
 Matthew Klinge, BS⁴
 Linda Greenbaum, MD¹
 Scott Goldstein, MD³
 David Kastenber, MD¹

¹Division of Gastroenterology and Hepatology, ²Department of Pathology, Anatomy, and Cell Biology, ³Department of Surgery, Thomas Jefferson University Hospital, Philadelphia, Pennsylvania; ⁴Jefferson Medical College, Thomas Jefferson University, Philadelphia, Pennsylvania

Idiopathic myointimal hyperplasia of mesenteric veins (IMHMV) is a rare condition that primarily affects middle-aged men. IMHMV is typically associated with symptoms of abdominal pain, rectal bleeding, and diarrhea and endoscopic findings of severe inflammation, ulceration, and pseudopolyps. However, these clinical symptoms and endoscopic findings are also suggestive of ulcerative colitis and Crohn's disease, which are much more common than IMHMV. Thus, patients with IMHMV are often misdiagnosed with inflammatory bowel disease that is refractory to medical treatment. IMHMV can be definitively differentiated from inflammatory bowel disease only after histologic examination of specimens from the resected colon. In most IMHMV patients, disease is restricted to the sigmoid colon, but this case reports IMHMV in a patient with pancolitis.

Case Report

A 62-year-old man with a history of ulcerative colitis presented to the emergency department with hematochezia and crampy abdominal pain that was relieved with defecation. The bleeding began the evening prior to presentation and consisted of 3 large, bloody bowel movements. The patient's medical history included aortic valve replacement with a mechanical valve 4 years prior to presentation, paroxysmal atrial fibrillation, hypertension, and hyperlipidemia. The patient was receiving anticoagulation therapy with warfarin, although administration of this therapy was inconsistent due to repeat episodes of

rectal bleeding since his diagnosis with ulcerative colitis. At presentation, the patient's medications included warfarin, hydrocortisone suppositories, mesalamine suppositories, oral mesalamine, esomeprazole, iron sulfate, metoprolol, and prednisone (50 mg daily). The patient had a 60-pack-per-year history of cigarette use until 9 years prior to presentation. He denied any alcohol use or illicit substance abuse. He did not have a family history of gastrointestinal disorders, and he did not have any known drug allergies.

The patient had been diagnosed with ulcerative colitis 10 months earlier when he had presented to another hospital with bloody diarrhea and had undergone a colonoscopy and biopsy. The patient was initially treated with oral mesalamine, but he failed to respond to treatment; 1 month later, he started taking infliximab (Remicade, Janssen Biotech; 5 mg/kg). He continued to have frequent bloody bowel movements, and he lost 20 lbs over the next month.

Eight months prior to the current presentation, the patient was admitted to our hospital with bloody diarrhea, hypotension, leukocytosis, and fever. He was diagnosed with a *Clostridium difficile* infection based on results of a stool enzyme immunoassay, and he was successfully treated with oral metronidazole. Although his diarrhea resolved, he continued to experience intermittent bloody bowel movements and progressive weight loss. A colonoscopy revealed extensive inflammatory changes with pseudopolyposis, which spared the rectum and were suggestive of inflammatory bowel disease; the terminal ileum was intubated and appeared to be normal. Biopsies revealed mildly active colitis without granulomas or dysplasia. The patient was discharged on oral steroids and mesalamine.

Address correspondence to:

Dr. Jason Korenblit, Division of Gastroenterology and Hepatology, Thomas Jefferson University Hospital, 132 S. 10th Street, Suite 480, Philadelphia, PA 19107; Tel: 215-955-8900; Fax: 215-503-3746; E-mail: jasonkorenblit@gmail.com

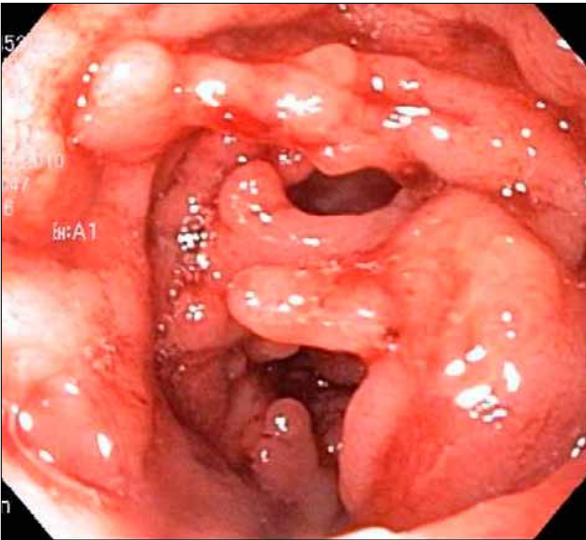


Figure 1. Pseudopolyps and bridging seen on flexible sigmoidoscopy.

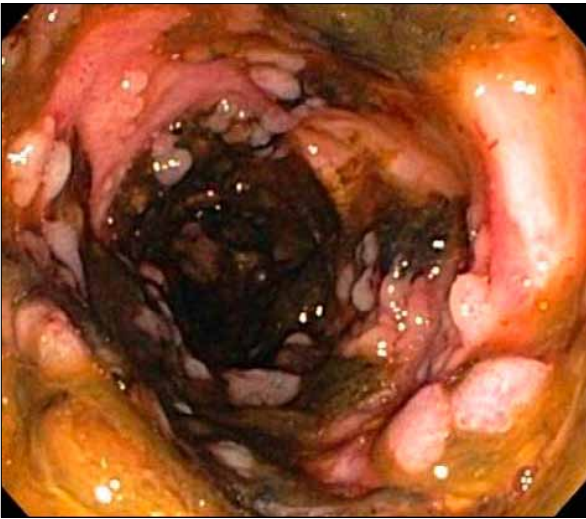

Figure 2. Cobblestoning seen on flexible sigmoidoscopy.

One month later, the patient presented with bloody diarrhea and underwent an outpatient colonoscopy. Again, innumerable pseudopolyps were seen on colonoscopy, as were several bridging folds and focal luminal narrowing 20 cm from the anus (Figure 1). Despite these extensive chronic findings, there was very little active mucosal inflammation other than mild, patchy friability. Biopsies revealed chronic colitis with patchy, mild activity. Testing for *C. difficile* infection was negative.

Over the next several months, the patient continued to be moderately symptomatic, with continued weight loss and approximately 4 bowel movements per day with intermittent bleeding despite ongoing steroid use and infliximab therapy (5 mg/kg) every 6 weeks. A colonoscopy showed no endoscopic

improvement (Figure 2); likewise, histologic findings were unchanged. A biopsy specimen tested negative for cytomegalovirus infection, and no viral inclusions were seen on microscopy. Serologic testing was negative for antineutrophil cytoplasmic antibody, positive for anti-*Saccharomyces cerevisiae* immunoglobulin (Ig) A antibody (ASCA; 30.1 units), and strongly positive for ASCA IgG (50.4 units). Due to the patient's intractable symptoms and progressive weight loss, he was referred for a total proctocolectomy with ileostomy.

Prior to his scheduled surgery, the patient presented to our hospital with hematochezia (the current presentation). A physical examination revealed a thin white male who appeared chronically ill but was in no acute distress. The patient had a temperature of 97.8°F, pulse rate of 106 beats per minute, blood pressure of 115/64 mmHg, respiration rate of 18 breaths per minute, and oxygen saturation of 100% on room air. His mucous membranes were dry, and he had no axillary sweat. His pulmonary examination revealed clear lungs, and his cardiovascular examination revealed a mechanical S2, III/VI systolic ejection murmur and tachycardia. The patient's abdominal examination revealed normal bowel sounds; the abdomen was soft with mild tenderness in the left lower quadrant and no rebound or guarding. His skin examination was normal, and his extremities were without clubbing, cyanosis, or edema. His rectal examination revealed no stool, but a small amount of blood was present in the vault.

Laboratory tests revealed a white blood cell count of 12.8 B/L (normal, 4–11 B/L), hemoglobin level of 6.7 g/dL (normal, 12.5–15 g/dL), and platelet count of 460 B/L (normal, 400 B/L). The patient's levels of electrolytes and creatinine were within normal limits, his prothrombin time was 19.7 seconds, and his international normalized ratio was 1.72. His liver enzyme levels were normal, and his albumin level was 2.3 g/dL (normal, 3.2–4.9 g/dL).

The patient was admitted and stabilized with intravenous fluids and a transfusion of packed red cells. He had no further bleeding episodes. His stool tested negative for bacterial pathogens, including *C. difficile*. A flexible sigmoidoscopy again revealed extensive colonic pseudopolyposis, which now also involved the rectum, and a strictured segment 15 cm proximal to the anus, beyond which the sigmoidoscope could not be advanced. No biopsies were taken because the patient was scheduled to undergo surgery the following day.

On the fourth day in the hospital, the patient underwent a laparoscopically assisted total proctocolectomy with a right lower quadrant Brooke ileostomy. The patient tolerated the procedure well and was discharged home 4 days after the operation.

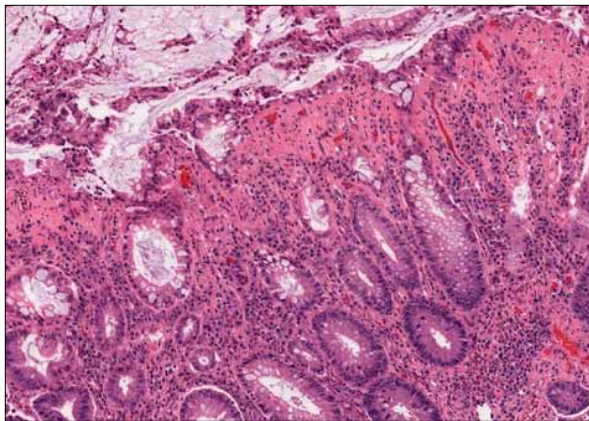


Figure 3. Lamina propria hyalinization and crypt withering indicative of mild mucosal ischemia (hematoxylin and eosin stain, 10× magnification).

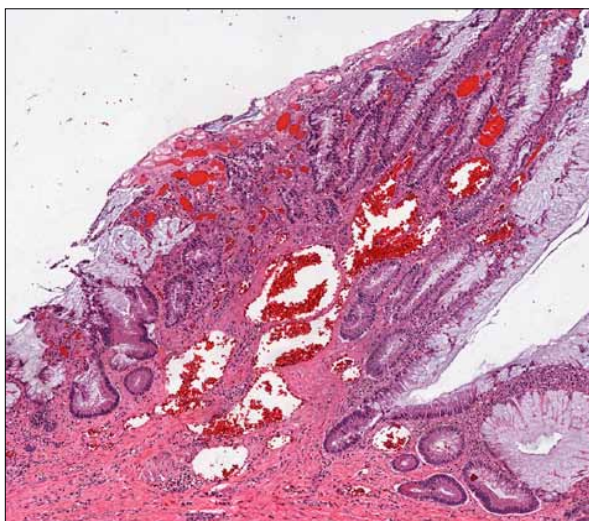


Figure 4. Ectatic blood vessels in the mucosa and submucosa (hematoxylin and eosin stain, 4× magnification). This histologic change may be due to increased resistance to intestinal blood flow.

A gross pathologic examination of the resected colon revealed erythematous, ulcerated, and friable mucosa throughout the colon, with sparing of the distal anus and terminal ileum. The left colon was most severely ulcerated and hemorrhagic, with areas of cobblestoning and extensive pseudopolyps. Histologically, the sigmoid colon lacked significant crypt architectural distortion, Paneth cell metaplasia, and muscularis mucosa hypertrophy, all of which are characteristic of inflammatory bowel disease. Moreover, there was no active acute inflammation. Sections from the left colon showed patchy, smudgy hyalinization of the lamina propria and withering of the superficial portion of the crypts, which are indicative of mild mucosal ischemia

(Figure 3). A trichrome stain demonstrated increased submucosal fibrosis, which is a feature of chronic ischemia. In contrast, inflammatory bowel disease usually manifests with muscularis mucosa hypertrophy without increased submucosal fibrosis.

Furthermore, histologic findings included thickened and ectatic blood vessels in the submucosa and mucosa, a feature of IMHBMV that is thought to be due to increased resistance to intestinal blood flow (Figure 4). Histology also identified myointimal hyperplasia with obliteration of the lumen of small and medium veins in the pericolonar fat; this histologic feature is pathognomonic of IMHBMV (Figure 5). An elastin stain confirmed that the process was limited to the veins (Figure 6). A smooth muscle actin stain demonstrated concentric proliferation of smooth muscle in the intima and media of the pericolonar mesenteric veins, highlighting the profound narrowing of the venous lumens. Fourteen lymph nodes were examined, and all tested negative for malignancy. Due to all of these findings, the presurgical diagnosis of ulcerative colitis was replaced with a diagnosis of IMHBMV.

Discussion

IMHBMV is a very rare condition that mimics inflammatory bowel disease, specifically ulcerative colitis. IMHBMV is often difficult to clinically or endoscopically distinguish from inflammatory bowel disease; a definitive diagnosis of IMHBMV requires pathologic examination of the resected colonic specimen.¹⁻³ The precise incidence of IMHBMV is unknown, as only 8 cases have been reported in the literature to date.^{4,5}

IMHBMV was first described by Genta and Haggitt in 1991 in a case series of 4 male patients ranging in age from 25 years to 67.2 years.⁴ Involvement was limited to the rectosigmoid colon in all 4 patients. The patients' clinical and endoscopic features were consistent with those of ulcerative colitis, but their biopsy results were inconclusive. On postoperative pathology, all specimens showed areas of focal ischemia and myointimal hyperplasia of mesenteric venules with little evidence of active inflammation. The average time from initial symptoms to surgical intervention ranged from 1 month to 6 months, and there was no disease recurrence in up to 7 years of follow-up.⁴

The histologic hallmark of IMHBMV is hypertrophy of the intimal layer of the mesenteric veins without surrounding venulitis or involvement of the arteries.⁵ The extent of intimal hyperplasia and venous obstruction varies but is present (to some degree) in all of the small and medium venules. A smooth muscle actin immunohistochemical stain can be used to confirm concentric

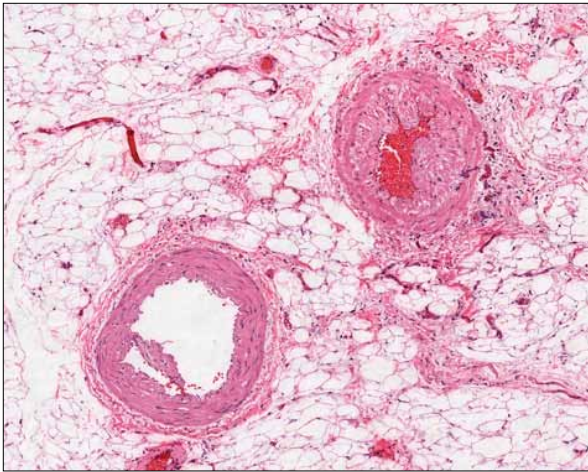


Figure 5. Myointimal hyperplasia in the vein (right; hematoxylin and eosin stain, 10× magnification). The artery is unaffected (left).

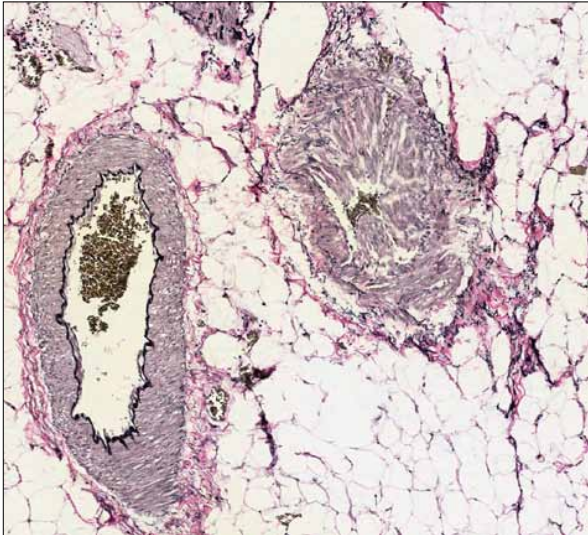


Figure 6. An elastin stain readily differentiates a vein from an artery by showing the absence of an arterial elastic lamina. In this Elastic Van Gieson stain (10× magnification), myointimal hyperplasia in the vein almost occludes the lumen (right). The artery is unaffected (left).

proliferation of smooth muscle cells in the intima and media of medium-sized intramural/mesenteric veins. As shown in our patient, endoscopic biopsies are inadequate for establishing the diagnosis of IMHBMV.

The pathophysiology of IMHBMV is speculative. A case series suggested that nonsteroidal anti-inflammatory drugs (NSAIDs) may play a role, but our patient reported no regular use of NSAIDs.⁵ Abu-Alfa and colleagues observed that the histopathologic changes seen

in IMHBMV patients are very similar to those seen in explants with failed saphenous vein grafts from coronary artery bypass specimens.⁶ These veins also show the characteristic luminal ablation by hyperplastic smooth muscle tissue that stains positive for smooth muscle actin and collagen type IV. However, no arteriovenous malformations were identified in our patient during resection. The predominance of IMHBMV in the rectosigmoid colon has led some researchers to propose that increased mobility of this colonic segment results in repeated trauma to the vessels and, in turn, occult arteriovenous fistula formation or focal hypoxia that leads to intimal hyperplasia.⁷

An interesting, and perhaps related, disease entity is mesenteric inflammatory veno-occlusive disease, another acquired disorder of mesenteric venules that also mimics inflammatory bowel disease. Occurring equally in men and women, this disorder often presents with a fulminant clinical course and progresses over weeks.⁸ Sites of involvement can include both the colon and the small bowel. This condition parallels IMHBMV in that only small and medium venules are involved and the arterial system is spared. However, vascular inflammation is present, with a lymphocytic or neutrophilic infiltrate. Most vessels also demonstrate myointimal hyperplasia, and there is no systemic or skin involvement in the vasculitic process.⁹ Due to the rarity of both conditions, it is unclear whether they are simply different spectrums of the same disorder or whether they are separate disease processes.

Although IMHBMV has been limited to the sigmoid colon in past reports, our patient had a diagnosis of pancolitis at the time of proctocolectomy, which is a novel presentation of IMHBMV. Even though our patient's age was at the upper limit of the ages of IMHBMV patients reported thus far, his clinical course and mimicry of inflammatory bowel disease were consistent with past reports of IMHBMV. The chronic mucosal changes associated with inflammatory bowel disease were present, and the severity of our patient's symptoms appeared somewhat greater than the degree of mucosal inflammation. As with past cases, traditional therapies for inflammatory bowel disease—steroids and mesalamine—failed to induce remission. The anti-tumor necrosis factor agent infliximab was also ineffective in our patient. As with past cases, the diagnosis was established after pathologic resection revealed hyperplasia of the myointimal layer of the mesenteric veins and complete sparing of the arterial vasculature.

Treatment of IMHBMV patients with surgical resection limited to the affected colonic segment has been successful.¹⁰ Follow-up for up to 7 years after resection has not revealed any disease recurrence.⁴ Our patient required total proctocolectomy because he had

pancolonic involvement and was considered to be a poor candidate for an ileal pouch–anal anastomosis.

Summary

IMHBMV is a rare condition but one that should be considered in the differential diagnosis of colonic inflammatory bowel disease that is refractory to standard therapy, particularly disease limited to the rectosigmoid colon. It may not be possible to establish the diagnosis of IMHBMV prior to surgical resection or a full-thickness biopsy, but maintaining a high clinical suspicion may spare patients ineffective treatment. Surgical resection is the mainstay of therapy for IMHBMV patients, and there have not been any reports of postoperative disease recurrence.

References

1. Kornbluth A, Sachar DB; Practice Parameters Committee of the American College of Gastroenterology. Ulcerative colitis practice guidelines in adults (update):

- American College of Gastroenterology, Practice Parameters Committee. *Am J Gastroenterol.* 2004;99:1371-1385.
- Schwartz DA, Loftus EV Jr, Tremaine WJ, et al. The natural history of fistulizing Crohn's disease in Olmsted County, Minnesota. *Gastroenterology.* 2002;122:875-880.
- Lichtenstein GR, Hanauer SB, Sandborn WJ; Practice Parameters Committee of American College of Gastroenterology. Management of Crohn's disease in adults. *Am J Gastroenterol.* 2009;104:465-483; quiz 464, 484.
- Genta RM, Haggitt RC. Idiopathic myointimal hyperplasia of mesenteric veins. *Gastroenterology.* 1991;101:533-539.
- Kao PC, Vecchio JA, Hyman NH, West AB, Blaszyk H. Idiopathic myointimal hyperplasia of mesenteric veins: a rare mimic of idiopathic inflammatory bowel disease. *J Clin Gastroenterol.* 2005;39:704-708.
- Abu-Alfa AK, Ayer U, West AB. Mucosal biopsy findings and venous abnormalities in idiopathic myointimal hyperplasia of the mesenteric veins. *Am J Surg Pathol.* 1996;20:1271-1278.
- Chang KM. New histologic findings in idiopathic mesenteric phlebosclerosis: clues to its pathogenesis and etiology—probably ingested toxic agent-related. *J Chin Med Assoc.* 2007;70:227-235.
- Flaherty MJ, Lie JT, Haggitt RC. Mesenteric inflammatory veno-occlusive disease. A seldom recognized cause of intestinal ischemia. *Am J Surg Pathol.* 1994;18:779-784.
- Lavu K, Minocha A. Mesenteric inflammatory veno-occlusive disorder: a rare entity mimicking inflammatory bowel disorder. *Gastroenterology.* 2003;125:236-239.
- Savoie LM, Abrams AV. Refractory proctosigmoiditis caused by myointimal hyperplasia of mesenteric veins: report of a case. *Dis Colon Rectum.* 1999;42:1093-1096.

Review

Idiopathic Myointimal Hyperplasia of Mesenteric Veins

Joseph Platz, MD

Neil Hyman, MD, FACS

Department of Surgery

University of Vermont College of Medicine

Burlington, Vermont

Idiopathic myointimal hyperplasia of mesenteric veins (IMHBMV) is an uncommon and poorly understood disease that classically occurs in the rectosigmoid colon of relatively young, otherwise healthy males. The clinical presentation of IMHBMV mimics that of inflammatory bowel disease, and colon resection has been invariably required in these patients after a prolonged course of failed medical therapy. The etiology of IMHBMV is unknown, and this condition has been diagnosed only after histopathologic review of the resected colon.¹

IMHBMV was first reported in 1991 by Genta and Haggitt, and fewer than a dozen case reports have subsequently been published in the literature.² The clinical course of this disease is usually characterized by protracted abdominal pain, weight loss, and bloody diarrhea in young, previously healthy men, although IMHBMV has more recently been reported in older patients, including women.³⁻⁶ Segmental involvement of the rectosigmoid colon is most commonly reported, although involvement of the ileum has also been described.⁵ IMHBMV is routinely mistaken for inflammatory bowel disease because of the similarity in age distribution, symptoms, and endoscopic findings. Friable, edematous, and erythematous colonic mucosa is commonly observed early in the disease course, followed later by patchy ulcerations and inflammatory exudate.^{1,7}

An important clue when differentiating inflammatory bowel disease from IMHBMV comes from the evaluation of biopsies, as the typical endoscopic features of ulcerative colitis or Crohn's disease are notably absent in patients with IMHBMV. Although specific criteria for the diagnosis of IMHBMV based on mucosal biopsies have been reported, biopsy findings are usually nonspecific or suggest an ischemic etiology.^{1,3,8} The key point for the clinician is that the biopsies do not support the presumptive diagnosis of inflammatory bowel disease. Fortunately,

Address correspondence to:

Dr. Neil Hyman, 111 Colchester Avenue, Mailstop 320FL4, Burlington, VT 05401; Tel: 802-847-0819; Fax: 802-847-5579; E-mail: neil.hyman@vtmednet.org

surgery appears to be curative, as disease recurrence after resection has not been described to our knowledge.

It is quite difficult to determine the true incidence of IMHBMV, as this condition has only been diagnosed to date in patients who experience a complication that requires colon resection. It is possible that there are milder forms of IMHBMV that do not have the virulent nature of the cases reported in the literature, as the diagnosis of this condition has routinely been established only after histopathologic review of the colectomy specimen. Endoscopic biopsy findings of IMHBMV are subtle and consist of congestion, ischemic change, and regenerative mucosal changes; however, there is no sign of chronicity to suggest inflammatory bowel disease. High-power magnification reveals numerous prominent dilated vessels that are diffusely distributed throughout the lamina propria. As opposed to the dramatic and “spectacular” findings noted in the veins of the surgical specimen, the mucosal changes are relatively nonspecific.¹

The pathognomonic findings in the resected specimen consist of nonthrombotic, noninflammatory occlusion of the mesenteric veins secondary to intimal smooth muscle hyperplasia. In other settings when venous occlusion leads to ischemic bowel, there is mesenteric vein thrombosis.⁹ On routine hematoxylin and eosin stains, the characteristic venous occlusion/hyperplasia can be mistaken for the more common findings of arterial occlusion even when actin staining is used for smooth muscle identification, potentially creating diagnostic confusion.⁷ Therefore, in cases of suspected IMHBMV, elastin stains are particularly valuable for differentiating arterial from venous blood vessels.¹⁰

Nonthrombotic mesenteric vein occlusion has been shown to occur in forms of systemic vasculitis, such as Behçet disease, systemic lupus erythematosus, and enterocolic lymphocytic phlebitis.^{2,8} These disorders, which are known as mesenteric inflammatory veno-occlusive diseases, have unique patient demographics, unique distribution of disease, and a characteristic lymphocytic infiltrate on histology that is not present in IMHBMV samples.^{11,12} Mesenteric inflammatory veno-occlusive diseases are rare conditions that occur without gender preference, across a wide age distribution, and involve different segments of the small and large intestines; there is no known relationship between this inflammatory phlebitis and the noninflammatory changes of IMHBMV.

Abu-Alfa and associates initially hypothesized that IMHBMV is caused by acquired segmental arteriovenous fistulization secondary to trauma because mesenteric veins in patients with this disease closely resemble arterIALIZED vessels from saphenous vein bypass grafts or dialysis fistulae.^{8,13,14} Focal myointimal hyperplasia

has been shown to occur more often in bowel patients who have undergone trauma prior to resection such as previous surgery, incarceration, or intussusception.⁷ A retrospective angiographic review of a patient with IMHBMV revealed a tortuous, enlarged marginal artery in the region of the rectosigmoid colon, but there was no obvious sign of early venous filling.¹⁵

Korenblit and colleagues presented a case report of a 62-year-old man with IMHBMV.⁶ As is usual in this condition, the signs, symptoms, and endoscopic findings were strongly suggestive of inflammatory bowel disease. The patient's presentation of crampy abdominal pain and bloody stools, endoscopic findings consistent with inflammatory bowel disease, and prolonged unsuccessful treatment with 5-aminosalicylic acid, steroids, and biologic agents are all routine for patients who are ultimately diagnosed with IMHBMV. The figures in this case report show inflammatory pseudopolyps and cobblestoning of the mucosa, which certainly resemble endoscopic findings of inflammatory bowel disease. The finding of chronic active colitis on biopsies taken 8 months prior to presentation makes this case challenging, as mucosal changes in IMHBMV patients do not typically appear to support the diagnosis of inflammatory bowel disease and have been a “red flag” in previous reports.

Of note in this case report, the final colectomy specimen did not demonstrate mucosal findings suggestive of inflammatory bowel disease. There was no architectural distortion of the crypts or Paneth cell metaplasia. Whether the initial biopsies were misinterpreted or the findings were confounded by *Clostridium difficile* infection or another concomitant process is unclear, particularly since this patient had pancolitis rather than the more usual segmental disease. Figure 5 nicely exemplifies the myointimal hyperplasia causing obliteration of the lumen of the veins. An elastin stain confirmed that the changes were confined to the venous outflow.

In summary, IMHBMV should be suspected in young men presenting with proctosigmoiditis when biopsies are not consistent with inflammatory bowel disease. With increasing awareness, clinicians may be able to identify IMHBMV prior to complications that necessitate surgery. Having said that, there is no known medical cure for IMHBMV, as the few cases reported to date have not responded to the usual medical regimens for treatment of inflammatory bowel disease. As this disease becomes more widely recognized and reported, the pathogenesis, distribution of disease, natural history, and best treatment will hopefully become known. Fortunately, IMHBMV patients who have been resected appear to be cured, with no recurrence of disease-related activity or symptoms.

References

1. Kao PC, Vecchio JA, Hyman NH, West AB, Blaszyk H. Idiopathic myointimal hyperplasia of mesenteric veins: a rare mimic of idiopathic inflammatory bowel disease. *J Clin Gastroenterol*. 2005;39:704-708.
2. Genta RM, Haggitt RC. Idiopathic myointimal hyperplasia of mesenteric veins. *Gastroenterology*. 1991;101:533-539.
3. Feo L, Cheeyandira A, Schaffzin DM. Idiopathic myointimal hyperplasia of mesenteric veins in the elderly. *Int J Colorectal Dis*. 2012 May 6. Epub ahead of print.
4. Chiang CK, Lee CL, Huang CS, Huang SH, Wu CH. A rare cause of ischemic proctosigmoiditis: idiopathic myointimal hyperplasia of mesenteric veins. *Endoscopy*. 2012;44(suppl 2):E54-E55.
5. Lanitis S, Kontovounisios C, Karaliotas C. An extremely rare small bowel lesion associated with refractory ascites. Idiopathic myointimal hyperplasia of mesenteric veins of the small bowel associated with appendiceal mucocoele and pseudomyxoma peritonei. *Gastroenterology*. 2012;142:e5-e7.
6. Korenblit J, Burkart A, Frankel R, et al. Refractory pancolitis: a novel presentation of idiopathic myointimal hyperplasia of mesenteric veins. *Gastroenterol Hepatol (N Y)*. 2012;8:696-700.
7. Sherman J, Kao PC, West AB, Blaszyk H. Focal myointimal hyperplasia of mesenteric veins is associated with previous trauma in surgical specimens. *Pathol Res Pract*. 2006;202:517-522.
8. Abu-Alfa AK, Ayer U, West AB. Mucosal biopsy findings and venous abnormalities in idiopathic myointimal hyperplasia of the mesenteric veins. *Am J Surg Pathol*. 1996;20:1271-1278.
9. Grendell JH, Ockner RK. Mesenteric venous thrombosis. *Gastroenterology*. 1982;82:358-372.
10. Blaszyk H, West AB. Idiopathic myointimal hyperplasia of the mesenteric veins: a rare diagnostic pitfall. *Am J Gastroenterol*. 2005;100:1423-1424.
11. Haber MM, Burrell M, West AB. Enterocolic lymphocytic phlebitis. Clinical, radiologic, and pathologic features. *J Clin Gastroenterol*. 1993;17:327-332.
12. Flaherty MJ, Lie JT, Haggitt RC. Mesenteric inflammatory veno-occlusive disease. A seldom recognized cause of intestinal ischemia. *Am J Surg Pathol*. 1994;18:779-784.
13. Kern WH, Wells WJ, Meyer BW. The pathology of surgically excised aorto-coronary saphenous vein bypass grafts. *Am J Surg Pathol*. 1981;5:491-496.
14. Stracke S, Konner K, Köstlin I, et al. Increased expression of TGF-beta1 and IGF-I in inflammatory stenotic lesions of hemodialysis fistulas. *Kidney Int*. 2002;61:1011-1019.
15. Lavu K, Minocha A. Mesenteric inflammatory veno-occlusive disorder: a rare entity mimicking inflammatory bowel disorder. *Gastroenterology*. 2003;125:236-239.