

# Metastasis of Renal Cell Carcinoma to the Pancreas 13 Years Postnephrectomy

Anisha Thadani, MD<sup>1</sup>  
Shireen Pais, MD<sup>1</sup>  
John Savino, MD<sup>2</sup>

<sup>1</sup>*Division of Gastroenterology and Hepatobiliary Diseases,* <sup>2</sup>*Department of Surgery, New York Medical College, Valhalla, New York*

Metastatic lesions in the pancreas are uncommon, accounting for only 5% of all pancreatic malignancies. Renal cell carcinomas (RCCs) account for 2% of all cancers and have a predilection to metastasize to rare locations, including the pancreas. RCC is the most common primary tumor leading to solitary pancreatic metastasis. Although the majority of metastases occur within 3 years of radical nephrectomy, the appearance of metastatic disease many years after nephrectomy is a well-known feature of RCC. Since most pancreatic metastases are asymptomatic, routine long-term radiologic surveillance is necessary. We present a case of metastatic RCC to the pancreas that occurred 13 years postnephrectomy.

## Case Report

A 67-year-old asymptomatic woman was referred to our institution for evaluation of a new mass in the tail of the pancreas that had been identified via computed tomography (CT). Her past medical history was significant for diabetes mellitus, hypertension, peripheral vascular disease, carotid artery stenosis, coronary artery disease status post-bypass surgery, and a 5.5-cm RCC of the left kidney, for which she had undergone a left nephrectomy in 1997 (approximately 13 years earlier). Routine, noncontrast CT surveillance found interval growth of a previously noted right renal mass lesion and development of a new mass in the pancreatic tail. A repeat CT scan performed with intravenous contrast showed 2 cystic lesions in the right kidney and a 5.8-cm × 4.9-cm × 3.6-cm mass in the tail of the pancreas. The pancreatic mass appeared isodense to the

pancreas prior to contrast administration, was markedly hypervascular on arterial phase imaging, and was noted to extend into the adjacent splenic vein with an enhancing thrombus.

Endoscopic ultrasound was performed at our institution and revealed a well-defined, hypoechoic, homogeneous, vascular, lobulated mass measuring 4.2 cm × 3.8 cm in the tail of the pancreas. The mass appeared to invade the splenic vein (Figure 1). Fine-needle aspiration of the mass showed clusters of suspicious cells with mucin.

The patient subsequently underwent a distal pancreatectomy with splenectomy. The final surgical pathology showed metastatic clear-cell RCC among pancreatic islet cells infiltrating focally into peripancreatic adipose tissue and into the splenic vein with intravascular tumor nodule formation (Figure 2). Three peripancreatic lymph nodes, the splenic artery, and pancreatic resection margins were free of the tumor.

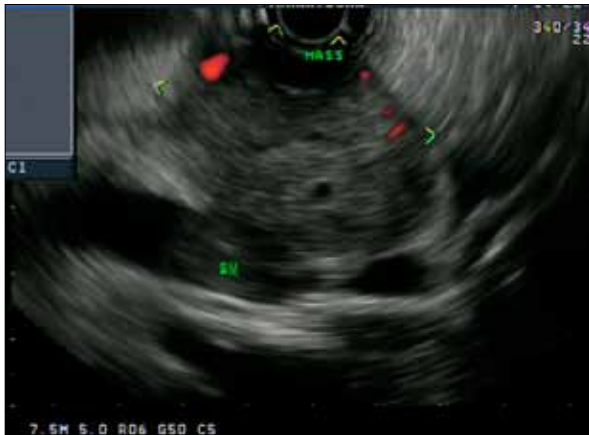## Discussion

RCC accounts for approximately 2% of all cancers in the United States, with an annual incidence rate of over 30,000 new cases per year; this rate has been steadily rising over the past 2 decades.<sup>1,2</sup> It is estimated that approximately one third of patients with RCC have metastases at presentation and that another 20–30% of patients with localized RCC will relapse after radical nephrectomy.<sup>3</sup> Approximately 85% of recurrences occur within 3 years of resection.<sup>1,4</sup> The most common sites of metastasis from RCC include the lung (50–60%), bone (30–40%), liver (30–40%), and brain (5%).<sup>1</sup> RCC also has a tendency to metastasize to rare sites, such as the pancreas, thyroid, skeletal muscle, skin, or soft tissue.<sup>1,5</sup>

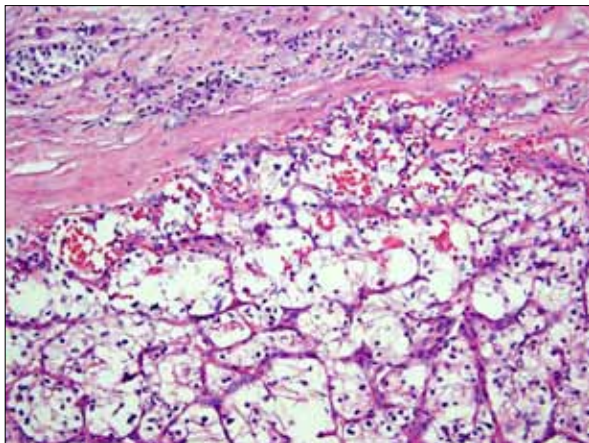
Metastasis to the pancreas is uncommon and accounts for 5% of all pancreatic malignancies.<sup>5</sup> Pancreatic

Address correspondence to:

Dr. Anisha Thadani, Division of Gastroenterology and Hepatobiliary Diseases, New York Medical College, Munger Pavilion, Suite 206, Valhalla, NY 10595; Tel: 914-493-7337; Fax: 914-594-4317; E-mail: anishathadani@gmail.com



**Figure 1.** An endoscopic ultrasound image showing a hypervascular mass in the tail of the pancreas invading the splenic vein (SV).



**Figure 2.** A low-power image showing a metastatic clear-cell renal cell carcinoma among pancreatic islet cells (hematoxylin and eosin stain).

metastases usually arise from breast cancer, colon cancer, non-small cell lung cancer, melanoma, or RCC.<sup>6</sup> In several case series, RCC has been cited as the most common primary tumor leading to solitary pancreatic metastasis, representing 0.25–3% of all resected pancreatic specimens.<sup>1,4,7</sup> Additionally, pancreatic metastases of RCC are often the sole site of distant spread.<sup>2</sup> The lesions can be multifocal in approximately 30% of patients and are resectable in approximately 80% of cases.<sup>7</sup>

RCC can recur any number of years after nephrectomy. The appearance of metastatic disease many years after nephrectomy is a well-known feature of RCC and is associated with a more favorable outcome than early recurrences, which tend to have more rapid progression of dis-

ease.<sup>4,5</sup> One study found that 11% of patients who survived 10 years or more after nephrectomy developed metastases, with an interval of up to 32 years in some reports.<sup>7,8,9</sup>

The mode of RCC spread to the pancreas remains controversial, although RCC has a predilection for both venous and lymphatic spread. Direct spread to the pancreas is not thought to occur.<sup>1,2</sup> Hematogenous spread may occur along the draining collateral veins via preexisting portacaval shunts.<sup>1,10</sup> Lymphogenous spread may occur via retrograde lymph flow through lymphatic routes from the head of the pancreas to the dorsal side of the renal artery.<sup>10</sup>

Patients may present with a variety of gastrointestinal symptoms, including abdominal pain, biliary obstruction, an abdominal mass, pancreatic exocrine/endocrine dysfunction, weight loss, and/or gastrointestinal bleeding secondary to hemosuccus pancreaticus.<sup>1</sup> Since pancreatic metastasis from RCC may be asymptomatic in up to 50% of cases, long-term follow-up surveillance with routine imaging is indicated.<sup>10</sup>

The radiologic features of metastatic RCC lesions closely resemble the appearance of primary RCC. CT imaging shows hyperenhancing lesions that are most pronounced in the early arterial phases of enhancement, which reflects the hypervascular nature of these tumors.<sup>1,4,10</sup> This feature aids in detecting RCC as well as distinguishing it from primary adenocarcinoma of the pancreas, which is typically hypovascular and appears nonenhancing on CT imaging.<sup>1,4,10</sup> Although radiologic features and clinical history can be strongly suggestive of RCC, histologic verification is mandatory. However, the risk of bleeding with fine-needle aspiration is increased due to the vascular nature of the tumor.<sup>10</sup>

Surgical treatment of isolated pancreatic metastases from neoplasms other than RCC carries a poor prognosis, as these metastases typically indicate disseminated metastatic disease.<sup>11</sup> Approximately 2–6% of patients with metastatic RCC present with isolated metastatic lesions amenable to surgical resection.<sup>3</sup> Surgical resection of metastatic disease limited to the pancreas has a 5-year survival rate of 29–35%.<sup>1,4,10</sup> Patients with isolated pancreatic metastases from RCC represent a unique group of patients with a more indolent course of RCC. A prolonged interval from nephrectomy to the appearance of metastasis is associated with a more favorable prognosis.<sup>10</sup> Radical lymph node dissection is not necessary, as peripancreatic lymph node involvement is uncommon, which may be one of the factors that explains the favorable outcomes achieved with surgery.<sup>1,2,10,11</sup>

## References

1. Kassabian A, Stein J, Jabbour N, et al. Renal cell carcinoma metastatic to the pancreas: a single-institution series and review of the literature. *Urology*. 2000;56:211-215.
2. Karimi KM, McFadden DW. Pancreatic resection for metastatic renal cell carcinoma to the pancreas. *Am Surg*. 2007;73:1158-1160.

3. Sohn TA, Yeo CJ, Cameron JL, Nakeeb A, Lillemoec KD. Renal cell carcinoma metastatic to the pancreas: results of surgical management. *J Gastrointest Surg.* 2001;5:346-351.
4. Ghavamian R, Klein KA, Stephens DH, et al. Renal cell carcinoma metastatic to the pancreas: clinical and radiological features. *Mayo Clin Proc.* 2000;75:581-585.
5. Tanis PJ, van der Gaag NA, Busch OR, van Gulik TM, Gouma DJ. Systematic review of pancreatic surgery for metastatic renal cell carcinoma. *Br J Surg.* 2009;96:579-592.
6. Thompson LD, Heffess CS. Renal cell carcinoma to the pancreas in surgical pathology material. *Cancer.* 2000;89:1076-1088.
7. Wente MN, Kleeff J, Esposito I, et al. Renal cell metastasis into the pancreas: a single-center experience and overview of the literature. *Pancreas.* 2005;30:218-222.
8. Bassi C, Butturini G, Falconi M, Sargenti M, Mantovani W, Pederzoli P. High recurrence rate after atypical resection for pancreatic metastases from renal cell carcinoma. *Br J Surg.* 2003;90:555-559.
9. McNichols DW, Segura JW, DeWeerd JH. Renal cell carcinoma: long-term survival and late recurrence. *J Urol.* 1981;126:17-23.
10. Faure JP, Tuech JJ, Richer JP, Pessaux P, Arnaud JP, Carretier M. Pancreatic metastasis of renal cell carcinoma: presentation, treatment and survival. *J Urol.* 2001;165:20-22.
11. Sellner F, Tykalsky N, De Santis M, Pont J, Klimpfinger M. Solitary and multiple isolated metastases of clear cell renal carcinoma to the pancreas: an indication for pancreatic surgery. *Ann Surg Oncol.* 2006;13:75-85.

## Review

### Metastatic Renal Cell Carcinoma to the Pancreas

Harish Lavu, MD  
Charles J. Yeo, MD

*Department of Surgery, Thomas Jefferson University and  
Jefferson Pancreas, Biliary, and Related Cancer Center,  
Philadelphia, Pennsylvania*

As discussed in the case report by Thadani and colleagues, isolated solid organ metastasis to the pancreas occurs infrequently in the absence of widely disseminated disease.<sup>1,2</sup> Of the primary tumors that can metastasize to the pancreas, renal cell carcinoma (RCC) is the most common, followed by lung cancer, breast cancer, colon cancer, and melanoma.<sup>3,4</sup> The incidence of primary RCC in the United States is approximately 50,000 new cases per year, accounting for 3% of all newly diagnosed malignancies.<sup>5</sup> Patients with RCC or other metastases to the pancreas are typically identified in 1 of 3 ways: The lesion is found during the initial staging work-up for treatment of the primary tumor; the lesion is discovered via routine follow-up imaging after the primary tumor has been treated; or the patient initially presents with symptoms related to the pancreatic lesion, which, on work-up, leads to the identification of the primary tumor. Minni and associates reported that 22% of patients with metastatic lesions to the pancreas were identified at the time of their primary tumor diagnosis.<sup>3</sup>

In many cases, it can be difficult to distinguish a pancreatic RCC metastasis from a primary pancreatic ductal

adenocarcinoma (PDA) or a neuroendocrine tumor (NET) of the pancreas. Patients may be completely asymptomatic, or they may develop symptoms of epigastric abdominal pain or acute pancreatitis secondary to pancreatic ductal obstruction from the metastatic lesion. Other potential signs and symptoms—such as early satiety, gastrointestinal bleeding, or painless jaundice secondary to biliary obstruction—can all be caused by either primary pancreatic neoplasia or isolated metastatic disease to the pancreas. Hiotis and colleagues found that 69% of patients with isolated pancreatic metastasis were completely asymptomatic at presentation.<sup>6</sup> For patients with primary RCC, the classic symptom triad of flank pain, gross hematuria, and a palpable mass are concurrently present in only 10% of all newly diagnosed cases. Other common symptoms include anemia, microscopic hematuria, and new-onset varicocele.<sup>7</sup> With the increased use of cross-sectional imaging technology in medicine today, a large number of primary RCCs and even their pancreatic metastases are being identified incidentally.

Cross-sectional radiographic imaging in these patients typically consists of abdominal magnetic resonance imaging/magnetic resonance cholangiopancreatogram or contrast-enhanced abdominal computed tomography with thin cuts through the pancreas. Via these imaging techniques, RCC metastatic disease to the pancreas can often be distinguished from PDA, as the former lesion is hypervascular (leading to contrast enhancement) while the latter lesion typically appears hypointense in the contrast phase. Metastases to the pancreas can be multicentric and typically do not cause peripancreatic lymphadenopathy; both of these findings can be used to distinguish metastases from PDA. Of note, pancreatic NETs are also

Address correspondence to:

Dr. Harish Lavu, Department of Surgery, Thomas Jefferson University, 1025 Walnut Street, College Building, Suite 605, Philadelphia, PA 19107; Tel: 215-955-9402; Fax: 215-923-6609; E-mail: harish.lavu@jefferson.edu

hypervascular and contrast-avid on cross-sectional imaging, such that distinguishing them from RCC metastases to the pancreas can be difficult.

Surgical resection of metastatic disease to the pancreas is appropriate in certain clinical scenarios, depending on the virulence of the primary tumor, the extent of metastatic disease, and the functional status of the patient. The specific type of surgical resection will depend on the location of the tumor within the pancreas. These procedures range from pancreaticoduodenectomy (for tumors in the head, neck, and uncinat process of the pancreas) to middle-segment or distal pancreatectomy (for tumors in the body and tail of the pancreas). In some instances, small isolated metastatic tumors to the pancreas can be treated with enucleation of the lesion, thereby preserving the pancreatic parenchyma. In cases of multicentric pancreatic metastases, total pancreatectomy has been performed, although this treatment approach is fairly uncommon.

Surgery is the principal treatment modality for primary RCC, and complete surgical resection via either partial or complete nephrectomy offers the possibility of cure. Unfortunately, 25% of patients with RCC have locally advanced or widely metastatic disease at the time of diagnosis, precluding surgical intervention.<sup>8,9</sup> The most common sites of RCC metastases are (in descending order) the lungs, lymph nodes, bone, liver, brain, ipsilateral adrenal gland, contralateral kidney, and pancreas.<sup>10</sup> In patients with RCC that is amenable to surgical treatment, the traditional therapeutic approach has been radical nephrectomy, including resection of Gerota fascia and the accompanying adrenal gland. This radical procedure is still performed for large tumors, but in most other settings, it has been replaced by less invasive adrenal-sparing and partial nephrectomy procedures, which are often performed using a laparoscopic approach. Adjuvant therapy (chemotherapy, immunotherapy, and/or radiation therapy) following surgical resection has shown disappointing results to date. Recently, there has been promising investigational research into molecular targeted therapy for RCC, specifically involving inhibition of the mammalian target of rapamycin pathway.<sup>11</sup>

Although metastasis to the pancreas is most commonly associated with disseminated systemic disease, RCC typically spreads to the pancreas as an isolated lesion, often making it amenable to surgical treatment.<sup>12</sup> Most cases of RCC metastasis to the pancreas present as metachronous lesions, often many years after resection of the primary tumor. The average time to presentation for pancreatic metastasis from RCC is 9.2 years after the initial resection.<sup>13</sup> Autopsy data have shown that 2% of patients with RCC have pancreatic metastases at the time of their death.<sup>14</sup> This finding highlights the importance of long-term postnephrectomy surveillance in patients with

RCC. When pancreatic spread of RCC is identified as a synchronous lesion, resection of the metastasis at the time of nephrectomy offers a survival benefit over nephrectomy alone.<sup>15,16</sup> The goals of pancreatic metastasectomy include resection of the lesion with clear surgical margins and preservation of as much viable pancreatic tissue as possible. Five-year survival rates after surgical resection of RCC metastasis to the pancreas are 53–75%, whereas patients who choose not to undergo surgical resection or who have widely disseminated disease have a 5-year survival rate of 5–30%.<sup>13,16,17</sup>

## Conclusion

When metastasis to the pancreas occurs, it is most commonly associated with widespread disease dissemination. RCC is the most common primary tumor to present with isolated solid metastasis to the pancreas. In a select group of patients with RCC metastasis to the pancreas, surgical metastasectomy can be performed safely and can improve long-term survival.

## References

1. Thadani A, Pais S, Savino J. Metastasis of renal cell carcinoma to the pancreas 13 years postnephrectomy. *Gastroenterol Hepatol (NY)*. 2011;7:697-699.
2. Rumanick WM, Megibow AJ, Bosniak MA, Hilton S. Metastatic disease to the pancreas: evaluation by computed tomography. *J Comput Assist Tomogr*. 1984;8:829-834.
3. Minni F, Casadei R, Perenze B, et al. Pancreatic metastases: observations of three cases and review of the literature. *Pancreatol*. 2004;4:509-520.
4. Moussa A, Mitry E, Hammel P, et al. Pancreatic metastases: a multicentric study of 22 patients. *Gastroenterol Clin Biol*. 2004;28:872-876.
5. Jemal A, Siegel R, Ward E, Murray T, Xu J, Thun MJ. Cancer statistics, 2007. *CA Cancer J Clin*. 2007;57:43-66.
6. Hiotis SP, Klimstra DS, Conlon KC, Brennan MF. Results after pancreatic resection for metastatic lesions. *Ann Surg Oncol*. 2002;9:675-679.
7. Cohen HT, McGovern FJ. Renal cell carcinoma. *N Engl J Med*. 2005;353:2477-2490.
8. Golimbu M, Al-Askari S, Tessler A, Morales P. Aggressive treatment of metastatic renal cell cancer. *J Urol*. 1986;136:805-807.
9. Campbell SC, Flanigan RC, Clark JL. Nephrectomy in metastatic renal cell carcinoma. *Curr Treat Options Oncol*. 2003;4:363-372.
10. Ritchie AW, Chisholm GD. The natural history of renal carcinoma. *Semin Oncol*. 1983;10:390-400.
11. Battelli C, Cho DC. mTor inhibitors in renal cell carcinoma. *Therapy*. 2011;8:359-367.
12. Law CH, Wei AC, Hanna SS, et al. Pancreatic resection for metastatic renal cell carcinoma: presentation, treatment and outcome. *Ann Surg Oncol*. 2003;10:922-926.
13. Showalter SL, Hager E, Yeo CJ. Metastatic disease to the pancreas and spleen. *Semin Oncol*. 2008;35:160-171.
14. Bennington JL. Proceedings: cancer of the kidney—etiology, epidemiology, and pathology. *Cancer*. 1973;32:1017-1029.
15. Sohn TA, Yeo CJ, Cameron JL, Nakeeb A, Lillemoe KD. Renal cell carcinoma metastatic to the pancreas: results of surgical management. *J Gastrointest Surg*. 2001;5:346-351.
16. Kavolius JP, Mastorakos DP, Pavlovich C, Russo P, Burt ME, Brady MS. Resection of metastatic renal cell carcinoma. *J Clin Oncol*. 1998;16:2261-2266.
17. Ritchie AW, deKernion JB. The natural history and clinical features of renal carcinoma. *Semin Nephrol*. 1987;7:131-139.