

Colonoscopic Perforation in Inflammatory Bowel Disease

Rohit Makkar, MD, and Bo Shen, MD

Dr Makkar is a fellow in the Department of Gastroenterology and Hepatology at The Cleveland Clinic Foundation in Cleveland, Ohio. Dr Shen is a professor of medicine and the Ed and Joey Story Endowed Chair at The Cleveland Clinic Foundation.

Address correspondence to:

Dr Bo Shen

Department of Gastroenterology and Hepatology-A31

The Cleveland Clinic Foundation

9500 Euclid Avenue

Cleveland, OH 44195;

Tel: 216-444-9252;

Fax: 216-444-6305;

E-mail: shenb@ccf.org

Abstract: Colonoscopy has become the diagnostic and therapeutic modality of choice in patients with inflammatory bowel disease (IBD) by allowing for the assessment of disease extent and activity; the distinction between ulcerative colitis, Crohn's disease, and other differential diagnoses; the surveillance of dysplasia; and the delivery of treatment (eg, stricture dilation). Colonoscopy-associated perforation is a dreaded complication associated with significant mortality and morbidity. Understanding and mitigating the risks of perforation in patients with IBD has become an important issue with the increasing use of immunomodulators and biologic agents. Studies have shown that patients with IBD are at a higher risk for perforation from diagnostic or therapeutic endoscopy than individuals in the general population. Reported risk factors associated with colonoscopic perforation include female sex, advanced age, severe colitis, use of corticosteroids, presence of multiple comorbidities, and stricture dilation. Disease-, technique-, and endoscopist-associated risk factors for perforation can be stratified and modified. This review, based on current available literature and the authors' expertise, should shed some light on the proper management of this challenging disease phenotype.

Colonoscopy is the main diagnostic and therapeutic modality for the management of inflammatory bowel disease (IBD). Colonoscopy with ileoscopy, together with other modalities, is an effective tool in the diagnosis and differentiation of ulcerative colitis (UC) from Crohn's disease (CD) in 85% to 89% of patients.¹⁻³ Diagnostic colonoscopy is an invaluable tool in the assessment of disease extent and activity, the identification of superimposed infection (such as cytomegalovirus), the monitoring of effectiveness of medical and surgical therapies, and the surveillance of colitis-associated neoplasia. In addition, therapeutic colonoscopy allows for the resection of discrete, isolated dysplastic polyps or adenomalike masses (ALMs) in patients with UC or CD and the dilation of IBD-related primary or secondary anastomotic strictures.

Keywords

Colonoscopy, Crohn's disease, endoscopy, inflammatory bowel disease, perforation, stricture dilation, ulcerative colitis

It is believed that medical therapy has a limited role in fibrostenotic CD. Conventional thought has been that the mechanical nature of a stricture requires a mechanical (endoscopic or surgical) intervention. Therapeutic endoscopy, however, is not without risk. Endoscopic polypectomy is associated with complication rates ranging between 0.7% to 2%, while rates of adverse effects associated with stricture dilation have been reported to be between 2% and 18%.⁴⁻¹³ Bowel perforation with resulting leakage of bowel contents into the peritoneal or mesenteric space can be devastating, with a reported mortality rate of 5%.¹⁴ With an increasing number of patients with IBD currently being treated with immunosuppressive agents such as corticosteroids, immunomodulators, and anti-tumor necrosis factor (TNF) biologic agents, the need to understand the prevalence of and identify the risk factors associated with endoscopic perforation is imminent. The purpose of this review is to present the current data on the prevalence and risk factors of bowel perforation in patients with IBD undergoing diagnostic and/or therapeutic endoscopic evaluation. Also discussed is our experience with the endoscopic treatment of a large cohort of patients with IBD and strictures. We then provide evidence- and experience-based recommendations for endoscopists to assist in the selection of appropriate patients and the use of proper endoscopic technique.

Etiology and Classification of Inflammatory Bowel Disease–Associated Strictures

The etiopathogenesis of IBD is under extensive investigation. Current hypotheses hold that IBD is associated with an aberrant mucosal immune response to altered gut microbiota in a genetically susceptible host. Intestinal strictures arise from a chronic transmural inflammatory process leading to tissue remodeling, mesenchymal cell hypertrophy, smooth muscle cell hyperplasia, and, ultimately, fibrosis.¹⁵ Transforming growth factor β has been shown to balance fibrogenesis and inflammation by signaling via SMAD-mediated proteins in the intestine. In CD, there is an imbalance of SMAD proteins that interfere with normal signaling. This leads to an excessive fibrosing response caused by fibroblast and smooth muscle cell activation and stricture formation. Treatment with infliximab (Remicade, Janssen Biotech)¹⁶ and corticosteroids¹⁷ has been shown to reduce the production of growth factors (such as vascular endothelial growth factor) that are implicated in the angiogenesis/fibrosis cascade and lead to the formation of strictures.¹⁸ Clinical, genetic, and serologic markers for the prediction of fibrostenosing CD have been reported.¹⁹ *NOD2* mutation is the most common genetic variant associated with an increased predisposition to fibrostenosis of the terminal ileum and subsequent

need for resection.¹⁹ Furthermore, genetic mutations of *NOD2/CARD15*, *ATG16L1*, *IBD5*, *DLG5*, and *IL-23R* have been reported to increase the risk of having fibrostenotic or fistulizing disease.¹⁹

As such, strictures are more commonly seen in CD and are anatomically predominant in the distal small bowel, enteroenteric (eg, ileocolonic) anastomosis, and distal rectum. Based on the Montreal Classification, CD can be categorized into inflammatory, fibrostenotic, and penetrating phenotypes.²⁰ Clinical phenotypes that result in a higher risk of intestinal fibrosis include ileal involvement, active smoking, a long duration of disease, the need for corticosteroid therapy, and the presence of family history of stricturing disease.²¹

Although the majority of patients have an inflammatory phenotype, a distinct fibrostenosing phenotype manifesting as progressive narrowing of the bowel lumen develops in more than one third of patients.¹⁶ Clinically, these CD-related strictures can be classified as either primary (de novo) or secondary (anastomotic or postsurgical) types. Pure fibrostenosing disease is present at diagnosis in approximately 10% of cases and may reach 20% to 30% after 10 years.²² Up to 80% of patients with CD will require at least 1 surgical resection within 10 years of their initial diagnosis.²³ Moreover, there is a high 1-year rate of postsurgical recurrence after bowel resection in CD, usually localized to the anastomotic or neoterminal ileal site. The recurrence of CD after intestinal resection has been studied, with an approximate 70% rate of endoscopic recurrence at 1 year and clinical recurrence developing in 20% to 60% of patients; in addition, 15% to 50% of patients will require further surgical intervention within 5 years.²⁴⁻²⁷ These postsurgical anastomotic strictures will require subsequent surgical intervention in at least 34% of cases.^{23,28} In addition to the inherent risk of the surgical procedure, 20% of patients may experience immediate postoperative complications such as anastomotic leakage and impaired wound healing, with a 30-day mortality rate of 3%.²⁹

Luminal strictures can occasionally occur in patients with UC, with a reported frequency ranging from 6.3% to 11%.^{30,31} These strictures can occur early or late in the course of the disease. Although some of the strictures result from hyperplasia of the muscularis mucosa, an aggressive evaluation of the stricture, including biopsy, is recommended in patients with chronic UC because such patients are at increased risk for dysplasia or carcinoma.³²

Therapeutic Colonoscopy in Patients with Inflammatory Bowel Disease

The main applications of therapeutic endoscopy in patients with IBD include balloon dilation of strictures and polypec-

tomy or endoscopic mucosal resection (EMR) of adenomas or isolated nodules. Endoscopic balloon dilation has been routinely performed in patients with IBD with small bowel or colonic strictures. The advent of through-the-scope (TTS) balloons allows for the nonoperative, pneumatic dilation of strictures, thereby deferring or, in the best of cases, avoiding invasive surgical interventions and their associated complications (such as short bowel syndrome). In primary and secondary strictures that are refractory to traditional endoscopic balloon dilation, our group has successfully used Doppler ultrasound-guided needle-knife therapy.³³

IBD is associated with an increased risk for the development of dysplasia, which often manifests as flat areas of dysplasia, dysplasia-associated masses or lesions, sporadic adenomas, or ALMs. Studies have shown that colonoscopic polypectomy for sporadic adenomas or ALMs appears to be a safe and effective treatment option.^{34,35} Polypectomy and EMR of isolated polypoid lesions also have been advocated in select patients. Hurlstone and colleagues prospectively evaluated colitis-associated Paris class 0 to II and Paris class I ALMs that were treated with EMR and noted a perforation rate of 0.6%.³⁶

Colonoscopic Perforation in the Non-Inflammatory Bowel Disease Population

A number of studies have evaluated risk factors associated with colonoscopic perforation in patients who do not have IBD. Reported rates of perforation during diagnostic, screening, or surveillance colonoscopy in the non-IBD population range between 0.09% and 0.2%.³⁷⁻⁴³ Compared with diagnostic colonoscopy alone, polypectomy or biopsy was shown to increase this risk by 1.9-fold.⁴⁴ Moreover, attempted resection of larger polyps, as well as those located in the right colon, contributes to a higher perforation risk. The number of polyps (1 vs ≥ 2), configuration (pedunculated vs sessile), histology (hyperplastic vs neoplastic), and the presence of associated malignancy also have been shown to increase the perforation rate.⁴⁵ Some studies have shown advanced age, female sex, the presence of multiple comorbidities, diverticulosis, and bowel obstruction to be associated with an increased risk of perforation even prior to any therapeutic intervention.⁴⁶ Levin and colleagues demonstrated that age was associated with a 5-fold increase in risk for perforation in a series of more than 16,000 colonoscopies performed in patients older than age 60 years.⁴⁴ In a retrospective, Medicaid population-based cohort study of 277,434 patients undergoing colonoscopy, Arora and colleagues³⁷ demonstrated that the prevalence of perforation increases after age 65 years (more so in patients older than age 80 years) in white persons compared with persons of African American descent and in men compared with women. The

authors also reported several other predictors for perforation, including advanced age, comorbidity, obstruction as an indication for the procedure, and performance of invasive interventions. Anderson and colleagues studied 10,486 colonoscopies and found that female sex was an independent risk factor for colonic perforation.¹⁰

Operator- and/or technique-dependent factors also have been investigated. Gastroenterologists appear to cause numerically fewer endoscopy-associated perforations than surgeons (0.03% vs 0.08%)³⁹ or internists (0.02% vs 0.06%).⁴ Although these findings cannot be directly extrapolated to patients with IBD, it is important to understand the impact they may have on decision-making by the endoscopist when a therapeutic colonoscopy is to be considered for any patient with IBD.

Perforation in Diagnostic Colonoscopy in Patients with Inflammatory Bowel Disease

The American Society for Gastrointestinal Endoscopy recommends endoscopy as an essential tool in the differential diagnosis and disease monitoring of IBD.³ Thukkani and colleagues⁴⁷ compared 4631 patients with CD and 6619 patients with UC to a control population of 826,207 patients without IBD. The authors found that patients with IBD undergoing colonoscopy tend to be younger, more likely to be white, and more likely to present to academic centers than to community or private practices. Due to the nature of their underlying disease, patients with IBD should be considered a distinct population with their own unique risk factors that need to be considered while undergoing diagnostic or therapeutic endoscopic evaluation.

To date, the literature regarding the prevalence and risk factors of perforation during endoscopy in the IBD population is limited. Arora and colleagues used a Medicare database to demonstrate a 0.06% perforation rate in patients undergoing a colonoscopy for the indication of IBD.³⁷ Previous, smaller case series have looked extensively into perforation risk in patients with IBD, with varying results. In an 85-patient case series, Carbonnel and colleagues⁴⁸ identified 1 perforation, which was attributed to persistent colonic dilation. Koobatian and colleagues described a single patient with a silent perforation that was attributed to an underlying stricture in their retrospective study of 384 patients with UC undergoing surveillance colonoscopies.⁴⁹ In a series of 151 colonoscopies and 70 polypectomies in patients with UC or Crohn's colitis, Rubin and colleagues³⁵ reported no perforations. Hardman and colleagues compared the safety of colonoscopy in patients with mild UC with those undergoing routine screening colonoscopies and those with other diseases.⁵⁰ The authors noticed

no significant difference in complication rate among the 3 groups. Terheggen and colleagues prospectively analyzed 558 consecutive patients to determine the safety of ileocolonoscopy in patients with diagnosed or suspected IBD and determined an overall perforation rate of 0.54%.⁵¹ Acute, severe UC with no procedure-related perforations was diagnosed in 41 (13.9%) of the 295 patients with UC. Of the 3 patients with perforations, 2 had CD-related strictures, and 1 had strictures that were associated with retroflexion in a severely inflamed rectum. Therefore, we suggest that narrow-caliber instruments (such as pediatric colonoscopes or gastroscopes) should be used in all patients with IBD to minimize the risk of perforation.

Due to the limited number of reported cases of colonoscopy-associated perforation in the literature, the majority of the previous single-center studies demonstrate a small number of incident cases and only univariable comparisons with controls at best. To conduct a multivariable analysis, the utilization of national databases may be a valid option. Our group studied the risk of perforation in a population-based study of patients with and without IBD from the National Inpatient Sample.⁵² The prevalence of colonic perforation in patients with IBD was determined to be 1% (compared with 0.6% in the control group, with an adjusted odds ratio of 1.83). The diagnosis of IBD was found to be an independent risk factor for perforation even after adjusting for age, sex, endoscopic dilation, and other medical comorbidities. On multivariate analysis, factors such as old age, female sex, and performance of endoscopic dilation were identified as independent risk factors for perforation in the IBD group. We also demonstrated, in a separate cohort with multivariate analysis, that severe disease on endoscopy and concurrent corticosteroid treatment were independently associated with an increased risk of perforation in 19 patients with IBD (12 CD and 7 UC).⁵³ These results suggest that extreme caution should be used when diagnostic or therapeutic colonoscopy is performed in patients with IBD, especially in older patients, those with severe disease, and those receiving corticosteroid therapy.

Perforation in Therapeutic Colonoscopy in Patients with Inflammatory Bowel Disease

A clinically relevant stricture is defined as a constant luminal narrowing with or without prestenotic dilation and obstructive clinical symptoms (abdominal pain, nausea, vomiting, and bloating). The goal of dilation is to provide relief from these symptoms while restoring the patency of the bowel lumen. The most common method of endoscopic dilation involves a TTS hydrostatic balloon that is inflated to 18 to 25 mm for several seconds to several minutes.

Colonoscopic stricture dilation can be safely performed in experienced hands. Breysem and colleagues⁵⁴ reported successful dilation in 16 (89%) of 18 patients with stenotic CD using an 18-mm diameter, 8-cm long TTS balloon. In only 8 (44%) of 18 patients was there sustained relief of obstructive symptoms after a mean follow-up of 25 months. It was found that dilation was more likely to be successful in patients with quiescent CD than active CD. Breysem and colleagues recommended that dilation of sharply angulated, long (>8 cm) strictures and those in areas of severe inflammation be avoided.⁵⁴ Thienpont and colleagues performed 237 dilations in 138 patients for clinically obstructive strictures (<5 cm, 84% anastomotic) and demonstrated a 2.5% perforation rate using smaller balloon sizes than those used by Couckuyt and colleagues while performing the dilations in a multistep fashion with a gradually increasing diameter, under visual control.^{55,56}

Dilating a stricture involves elongating and/or rupturing fibrous collagen-rich tissue. This process often provokes further inflammation and fibrosis at the stricture site. This may lead to recurrence, and, thus, some specialists have advocated the use of intralesional corticosteroid injections in an attempt to reduce local inflammation and prolong the efficacy of the dilation. Whether intralesional injection of long-acting corticosteroids following endoscopic dilation improves surgery-free survival is controversial. Singh and colleagues retrospectively analyzed 17 patients who underwent 29 stricture dilations (11 patients with 4 quadrant corticosteroid injections).⁵⁷ The stricture recurrence rate in the intralesional corticosteroid injection group was 10%, whereas it was 31.3% in the noncorticosteroid injection group. Of note, all of the perforations occurred in areas of active inflammation. As such, the authors concluded that strictures in areas of active inflammation might be prone to perforation in comparison with fibrotic strictures without marked superimposed mucosal inflammation. Importantly, the authors demonstrated no increase in the risk of perforation from either intralesional or systemic corticosteroid use.

In a statistically stronger, randomized study, East and colleagues assigned 13 patients to either an intralesional corticosteroid injection of triamcinolone 40 mg (n=7) or a saline placebo injection (n=6).⁵⁸ The authors demonstrated that a single treatment of intralesional corticosteroid injection did not reduce time to redilation after balloon dilation of Crohn's ileocolonic anastomotic strictures. In fact, the authors found a statistically insignificant trend toward a worse outcome in the corticosteroid injection group. In a prospective, randomized, control trial of 29 pediatric patients with stricturing CD, Di Nardo and colleagues demonstrated that patients with intralesional corticosteroid injection after endoscopic balloon dilation

Table 1. Perforation Rates in Endoscopic Dilatation of Strictures in Inflammatory Bowel Disease

Study	Patients, n	Stricture Dilations Performed	Maximum Balloon Size (mm)	Stricture Number	% Anas-tomotic Stricture	% Primary Stricture	Routine Cortico-steroid Injection	Perfora-tion Rate/ Patient (%)	Perfora-tion Rate/ Procedure (%)
Ramboer (1995) ⁷²	13	53	18	–	71	29	Yes	0	0
Couckuyt (1995) ⁵⁶	55	78	25	59	67	33	No	10.9	7.7
Dear (2001) ⁷³	22	71	18	–	95	5	No	0	0
Brooker (2003) ⁷⁴	14	26	20	–	79	21	Yes	0	0
Sabate (2003) ⁷⁵	38	53	25	41	65	35	No	2.6	1.9
Morini (2003) ⁷⁶	43	34	18	43	67	33	No	0	0
Thomas-Gibson (2003) ⁶¹	59	124	18	–	90	10	No	3.4	1.6
Nomura (2006) ⁷⁷	16	20	20	20	35	65	No	12.5	10.0
Singh (2005) ⁵⁷	17	29	18	20	35	65	Yes	1.8	10.3
Ferlitsch (2006) ⁷⁸	39	73	20	–	62	38	Yes	5	2.7
Ajlouni (2007) ⁷⁹	37	118	20	83	37	63	No	0	0
Foster (2008) ¹⁸	24	71	20	29	41	55	Yes	8.3	2.8
Mueller (2010) ⁸⁰	55	93	18	74	23	77	No	1.8	1.1
Stienecker (2009) ⁸¹	25	31	18	31	48	52	No	4	3.2
Scimeca (2011) ⁸²	37	72	20	39	90	10	No	0	0
Thienpont (2010) ⁵⁵	138	237	18	–	84	16	No	4.3	2.5
Atreja (2010) ⁸³	135	340	–	–	53	47	Yes	2.2	0.9
Shen (2011) ^{63*}	150	646	20	256	100	0	No	1.3	0.3

*Dilatation of ileal pouch strictures.

had a statistically longer time free of redilation and surgery without any increase in perforation risk.⁵⁹ Therefore, the data regarding the beneficial effects of intralesional corticosteroid injection remain mixed.

To date, there is significant inconsistency in the reports of risk factors associated with perforation from

therapeutic endoscopy in patients with IBD. Singh and colleagues suggested that dilation procedures involving an angulated stricture, multiple stricture dilations during a single session, and strictures in areas of active inflammation all presented an increased risk of perforation.⁵⁷ Hassan and colleagues showed an overall technical suc-

Table 2. Risk Factors for Perforation in Endoscopic Dilation of Strictures in Inflammatory Bowel Disease

Study	Reported Risk Factors
Couckuyt (1995) ⁵⁶	Ileosigmoidal/ileorectal strictures, balloon size, anesthesia
Thomas-Gibson (2003) ⁶¹	De novo strictures
Nomura (2006) ⁷⁷	Balloon size, de novo strictures
Singh (2005) ⁵⁷	Inflamed area, angulation, multiple dilations, passage of endoscope immediately after dilation
Ferlitsch (2006) ⁷⁸	Fistulae, passage of endoscope immediately after dilation
Foster (2008) ¹⁸	Complex anastomotic strictures
Stienecker (2009) ⁸¹	Multiple dilations
Shen (2011) ^{63*}	Multiple dilations, angulation

*Dilation of ileal pouch strictures.

cess rate (defined as the ability to complete the dilation) of 86% and a long-term clinical efficacy rate (defined as surgery-free time) of 58% with a mean follow-up of 33 months (corresponding to 800 patient-years follow-up) in a systemic review of 13 published studies inclusive of 347 patients with CD undergoing predominantly postsurgical endoscopic stricture dilation.¹³ The only predictor of surgery-free survival on multivariate analysis was stricture length. The overall perforation rate was 1.8% (13/700), with 2 series reporting rates greater than 10%.^{56,57} Of note, the studies included in this analysis had small sample sizes, with heterogeneous patient populations and dilation techniques and different endpoints, thereby making a comprehensive interpretation of the data difficult (Table 1 and Table 2). The risk of perforation associated with stricture dilation has yet to be systemically evaluated.

The contribution of concurrent immunomodulator therapy to perforation after stricture dilation is also not clear. Raedler and colleagues compared patients undergoing dilation while taking azathioprine and budesonide therapy with patients receiving dilation alone.⁶⁰ The authors demonstrated a perforation rate of 10.3%, with all of the complications noted to occur at sites of actively inflamed strictures. There was no association of increased perforation rate with concurrent immunomodulator or budesonide use. These findings are similar to those of separate studies by Thomas-Gibson and colleagues⁶¹ and Singh and colleagues,⁵⁷ which showed that the use of concurrent azathioprine or oral corticosteroids did not affect postdilation perforation rates. Outcomes of postperforation peritonitis in patients on concomitant immunosuppressive therapy have yet to be studied.

Perforation in Therapeutic Endoscopy in Patients with Ostomy or Ileal Pouches

Endoscopy is the main tool used in the differential diagnosis and treatment of diseases of the neoterminal ileum, neocolon, and ileal pouches. For patients with ileal pouches, sedated or unsedated endoscopy is usually performed in the outpatient setting with a more flexible, smaller-caliber gastroscope.⁶² CD-, nonsteroidal anti-inflammatory drug-, or ischemia-related strictures are common in patients with ileal pouches. The most common locations of these strictures are the anastomotic site, pouch inlet, or site of a previous ileostomy. Endoscopic stricture dilation, together with concurrent medical therapy (in the setting of CD), has been shown to be a safe and effective therapy in the prevention of pouch failure in the majority of patients.⁶³ Similar dilation techniques, as cited above, have been used to treat strictures in patients with Brooke ileostomies and colostomies. For patients with high-degree, multiple, or angulated strictures, wire-guided antegrade dilation without the use of fluoroscopy has previously been described.⁶⁴ For refractory fibrosteonic strictures, Doppler ultrasound-guided, endoscopic needle-knife stricturostomy treatment may be attempted.^{32,65}

Endoscopy-associated perforation can occur in patients during ileoscopy or pouchoscopy. Our personal experience suggests that patients undergoing dilation of multiple, angulated strictures and those with strictures at previous ileostomy sites may be at an increased risk for perforation.

Purported Risk Factors and Proposed Mechanisms of Perforation

Based on findings reported in the literature and our senior author's experience of more than 2000 endoscopic stricture dilations in patients with IBD, we propose the possible mechanisms of perforation below. Factors associated with bowel perforation during endoscopy in patients with IBD can be divided into those that are stricture- or disease-related versus those that are technique- or operator-related.

Disease- or Stricture-Related Factors

Perforations related to diagnostic colonoscopy in patients with and without IBD are often caused by mechanical trauma to the bowel wall. This occurs either directly from the tip or shaft of the endoscope or from barotrauma resulting from excessive air insufflation. The risk of barotrauma can be especially pronounced in patients who have a long and tortuous colon, have extensive diverticulosis with or without diverticulitis, undergo emergent bedside endoscopy, undergo an endoscopy with a prolonged procedure time, have acute ischemic colitis, have a stenotic lumen due to obstruction, have an incompetent or deformed ileocecal

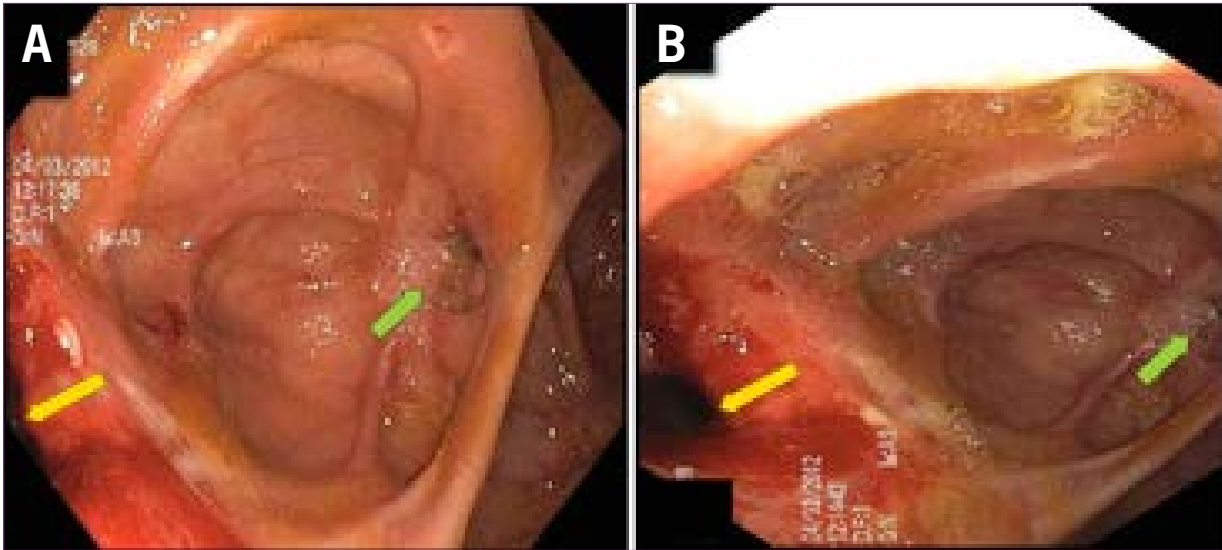


Figure 1. The ulcerated sinus at the stump of the ileocolonic anastomosis (green arrows) shown in **A** and **B** can easily be mistaken for an ulcerated anastomotic stricture. The true anastomosis is identified by the yellow arrows.

valve, and receive poor bowel preparation with excessive air insufflation. In these cases, a large amount of air can become trapped in an isolated portion of the bowel, leading to increased intraluminal pressure. The thin-walled cecum is particularly vulnerable to excessive air insufflation. Excessive looping can result in direct mechanical trauma to the colonic wall from the shaft of the endoscope.⁴⁴ Age-mediated degenerative changes in the myenteric plexus demonstrated by abnormal-appearing ganglia, a decrease in neuronal density, and an increase in the fibrous component of the neuron are hypothesized to lead to a decreased frequency of colonic contractions. This alters the elastic properties of the colon and makes it increasingly susceptible to the mechanical forces applied to the colonic wall during endoscopy.^{66,67} Female patients are thought to be more susceptible to these mechanical forces, as they have greater colonic length in spite of smaller stature, with a more rounded, deeper pelvis. These anatomic factors predispose women to more frequent sigmoid looping during endoscope advancement.^{10,68}

In patients with IBD, the following disease-specific factors can contribute to an increased risk of perforation during a diagnostic colonoscopy, based on limited literature and our own experience: history of multiple abdominal and pelvic surgeries; previous pelvic radiation; concurrent use of narcotic, corticosteroid, immunomodulator, or anti-TNF medications; the presence of de novo or anastomotic colonic strictures or ileocolonic anastomotic strictures; and severe bowel inflammation.⁵³

In therapeutic colonoscopy in patients who do not have IBD, polypectomy is the most common procedural intervention. With regard to electrocautery, the vast majority of polyps are removed with either hot biopsy forceps or thermal snares. Hot biopsy forceps combined

with pure coagulation current produce deeper tissue injury and higher rates of transmural damage in animal models compared with snares, bipolar electrocautery, or pure cut current.^{69,70} Monopolar hot biopsy forceps have been implicated in perforations of the right colon due to the thinner muscular wall. No greater advantage was seen between blended and pure coagulation current in a study that compared 1486 colonic snare polypectomies in patients who did not have IBD, although the finding was most likely related to the fact that there was a small overall incidence of perforations in the study population.⁷¹

When considering therapeutic colonoscopic intervention (mainly stricture dilation) in patients with IBD, the endoscopist should keep the following stricture- or disease-related factors in mind, as they may be associated with a higher risk of perforation and need for special precautions: the presence of multiple strictures; angulated single or multiple strictures; long (>2 cm) strictures; asymmetric anastomotic strictures (particularly stapled anastomosis); strictures associated with superimposed ulcers, fistulae, abscesses, or active inflammation; and ileocolonic anastomotic strictures or de novo colonic strictures.

Technique- or Operator-Related Factors

Diagnostic and therapeutic colonoscopy in patients with IBD can be technically demanding. No doubt, the risk of perforation is lower in experienced hands. The risk of perforation is higher and results in poorer outcomes in the following situations: if the operator lacks proper training in therapeutic endoscopy; the endoscopist rushes to complete the procedure; there is poor procedural coordination with the endoscopy nurses; there is excessive air insufflation and endoscopic looping; there is a lack of well-defined bowel anatomy

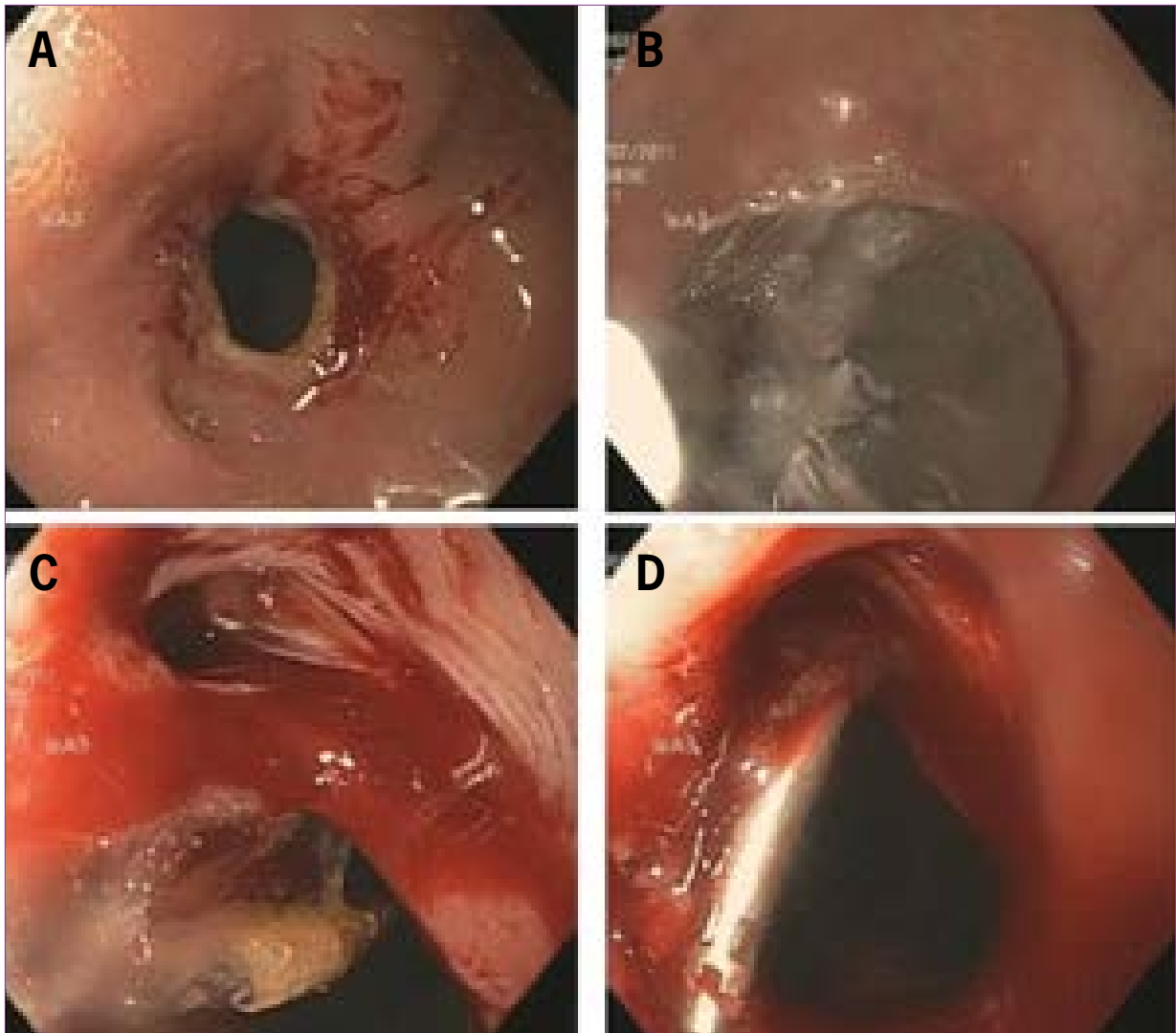


Figure 2. A: A fibrotic anastomotic stricture after colonoscopic balloon dilation. B: Balloon dilation. C: Immediate detection of a perforation at the dilation. D: Deployment of endoclips at the perforated site.

or landmarks prior to the procedure, especially in patients with multiple strictures (Figure 1) or in patients with altered bowel anatomy; the TTS balloon is insufflated too rapidly; improper instruments or supplies are used; and there is a lack of immediate surgical support in the case of a perforation.

Proposed Approach of Endoscopic Therapy to Inflammatory Bowel Disease–Related Strictures

Based on the available published data as well as our own vast experience, we propose the following suggestions to minimize the risk of colonoscopic perforation:

- Ensure an excellent bowel preparation, especially for patients undergoing therapeutic colonoscopy. The endoscopist should not be reluctant to reschedule the procedure if the bowel preparation is deemed to be suboptimal.
- Delineate the bowel anatomy as well as the location, length, and number of strictures present. Previous endoscopic and operative reports should be reviewed in addition to abdominal imaging. (Computed tomography and magnetic resonance imaging enterography are the preferred modalities.)
- Use minimal air insufflation and maintain a straight endoscope position.
- Use wire-guided TTS balloon dilation. Although the dilation of most IBD-related strictures requires large (18–20 mm) balloons, extreme caution should be used for asymmetric or stapled anastomotic strictures. For asymmetric or stapled anastomotic strictures, a smaller (12–15 mm) balloon should be used for the initial dilation. If the stricture is readily traversed with a pediatric colonoscope, an attempt should be made to perform the balloon dilation in

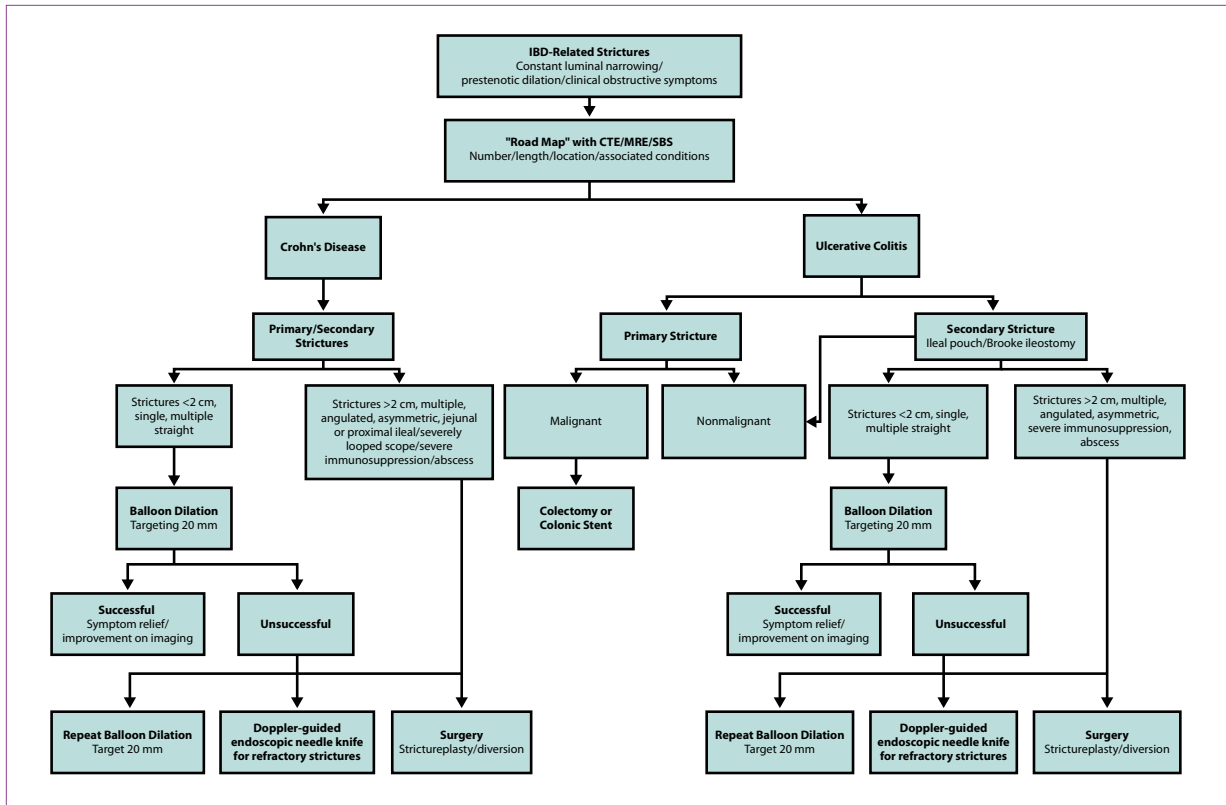


Figure 3. A proposed algorithm for the endoscopic management of inflammatory bowel disease (IBD)-related strictures. CTE, computed tomography enterography; MRE, magnetic resonance enterography; SBS, small bowel series.

a retrograde fashion by passing the colonoscope through the stricture and working backward so that the middle of the balloon is centered at the stricture. We believe that retrograde balloon dilation is safer than “blind” anterograde dilation. For tight strictures that cannot be traversed with a pediatric colonoscope, a wire-balloon exchange technique with a TTS balloon over a guidewire may be used for anterograde dilation. One should always consider using fluoroscopic guidance if available. The endoscopist should attempt to place the middle of the balloon at the narrowest point of the stricture.

- Gentle, slow TTS balloon insufflation resulting in obliteration of the “waist” (if performed under fluoroscopic guidance) should be performed for 5 to 10 seconds.
- Dedicated endoscopy nurses with experience in therapeutic colonoscopy should be involved. The coordination between dedicated endoscopy nurses and an experienced endoscopist is imperative for a safe and effective procedure.
- Avoid the immediate passage of the endoscope immediately after dilation.
- Immediate posttreatment assessment: some dilation-associated perforations can be recognized and managed during the endoscopic session. The perforation site can be therapeutically intervened upon with deployment of endoscopic clips (Figure 2).

- Damage control: if perforation is suspected, abdominal imaging (radiography or computed tomography based on institutional availability) should be performed.

We, therefore, propose an algorithm for the management of IBD-associated strictures (Figure 3).

Conclusions

Colonoscopy has been shown to be a safe and effective method of diagnosing and treating complications associated with IBD. Although the current data demonstrate that the overall risk of perforation in this patient population remains low, the significant morbidity associated with this complication, coupled with the increased risk of perforation, demands that higher-risk patients be identified and endoscopists understand the relative indications and contraindications of these procedures. In the general population, patient-specific risk factors for perforation include advanced age, female sex, presence of multiple medical comorbidities, diverticulosis, and bowel obstruction. In addition, endoscopist experience has been shown to have a direct influence on perforation rates. While these factors may not all be applicable to patients with IBD, they do require consideration. IBD-specific perforation risk factors for diagnostic colonoscopy include

active inflammation, concurrent corticosteroid use, older age, female sex, and performance of endoscopic dilation. Finally, with the advancement of TTS balloon dilation techniques for CD and reservoir-related strictures, caution should be used in the following settings: performance of dilation in patients with severe colitis; multiple, long, and/or angulated strictures; asymmetric, stapled anastomotic strictures; a torturous or poorly prepared colon; extensive abdominal or pelvic adhesions; incisional or ventral hernias; significant comorbidities; and multiple immunosuppressive agent use.

The authors have no conflicts of interest to disclose.

References

- Chutkan RK, Scherl E, Wayne JD. Colonoscopy in inflammatory bowel disease. *Gastrointest Endosc Clin N Am*. 2002;12(13):463-483.
- Pera A, Bellando P, Caldera D, et al. Colonoscopy in inflammatory bowel disease: diagnostic accuracy and proposal of an endoscopic score. *Gastroenterology*. 1987;92(1):181-185.
- Leighton JA, Shen B, Baron TH, et al. The ASGE guideline: endoscopy in diagnosis and treatment of inflammatory bowel disease. *Gastrointest Endosc*. 2006;63(4):558-565.
- Nelson DB, McQuaid KR, Bond JH, Lieberman DA, Weiss DG, Johnston TK. Procedural success and complications of large-scale screening colonoscopy. *Gastrointest Endosc*. 2002;55(6):307-314.
- Heldwein W, Dollhopf M, Rosch T, et al. The Munich Polypectomy Study (MUPS): prospective analysis of complications and risk factors in 4000 colonic snare polypectomies. *Endoscopy*. 2005;37(11):1116-1122.
- Macrae FA, Tan KG, Williams CB. Towards safer colonoscopy: a report on the complications of 5000 diagnostic or therapeutic colonoscopies. *Gut*. 1983;24(5):376-383.
- Basson MD, Etter L, Panzini LA. Rates of colonoscopic perforation in current practice. *Gastroenterology*. 1998;114(5):1115.
- Eckardt VF, Kanzler G, Schmitt T, Eckardt AJ, Bernhard G. Complications and adverse effects of colonoscopy with selective sedation. *Gastrointest Endosc*. 1999;49(5):560-565.
- Zubarik R, Fleischer DE, Mastropietro C, et al. Prospective analysis of complications 30 days after outpatient colonoscopy. *Gastrointest Endosc*. 1999;50(3):322-328.
- Anderson ML, Pasha TM, Leighton JA. Endoscopic perforation of the colon: lessons from a 10-year study. *Am J Gastroenterol*. 2000;95(12):3418-3422.
- Wayne JD, Lewis BS, Yessayan S. Colonoscopy: a prospective report of complications. *J Clin Gastroenterol*. 1992;15(4):347-351.
- Nivatvongs S. Complications in colonoscopic polypectomy. An experience with 1,555 polypectomies. *Dis Colon Rectum*. 1986;29(12):825-831.
- Hassan C, Zullo A, De Francesco V, et al. Systematic review: endoscopic dilatation in Crohn's disease. *Aliment Pharmacol Ther*. 2007;26(11-12):1457-1464.
- Fatima H, Rex DK. Minimizing endoscopic complications: colonoscopic polypectomy. *Gastrointest Endosc Clin N Am*. 2007;17(1):145-156.
- Thienpont C, D'Hoore A, Vermeire S, et al. Long-term outcome of endoscopic dilatation in patients with Crohn's disease is not affected by disease activity or medical therapy. *Gut*. 2010;59(3):320-324.
- Di Sabatino A, Cicciocioppo P, Benazzato L, Sturmiolo GC, Corazza GR. Infliximab downregulates basic fibroblast growth factor and vascular endothelial growth factor in Crohn's disease patients. *Aliment Pharmacol Ther*. 2004;19(9):1019-1024.
- Van Assche G, Geboes K, Rutgeerts P. Medical therapy for Crohn's disease strictures. *Inflamm Bowel Dis*. 2004;10(1):55-60.
- Foster EN, Quiros JA, Prindiville TP. Long-term follow-up of the endoscopic treatment of strictures in pediatric and adult patients with inflammatory bowel disease. *J Clin Gastroenterol*. 2008;42(8):880-885.
- Weersma RK, Stokkers PC, van Bodegraven AA, et al. Molecular prediction of disease risk and severity in a large Dutch Crohn's disease cohort. *Gut*. 2009;58(3):388-395.
- Silverberg MS, Satsangi J, Ahmad T, et al. Toward an integrated clinical, molecular and serological classification of inflammatory bowel disease: report of a Working Party of the 2005 Montreal World Congress of Gastroenterology. *Can J Gastroenterol*. 2005;19(suppl A):5-36.
- Fiocchi C, Lund PK. Themes in fibrosis and gastrointestinal inflammation. *Am J Physiol Gastrointest Liver Physiol*. 2011;300(5):G677-G683.
- Louis E, Collard A, Oger AF, et al. Behaviour of Crohn's disease according to the Vienna classification: changing pattern over the course of the disease. *Gut*. 2001;49(6):777-782.
- Farmer RG, Whelan G, Fazio VW. Long-term follow-up of patients with Crohn's disease. Relationship between the clinical pattern and prognosis. *Gastroenterology*. 1985;88(6):1818-1825.
- Cottone M, Orlando A, Viscido A, et al. Review article: prevention of postsurgical relapse and recurrence in Crohn's disease. *Aliment Pharmacol Ther*. 2003;17(suppl 2):38-42.
- Bernell O, Lapidus A, Hellers G. Risk factors for surgery and postoperative recurrence in Crohn's disease. *Ann Surg*. 2000;231(1):38-45.
- Borley NR, Mortensen NJ, Jewell DP. Preventing postoperative recurrence of Crohn's disease. *Br J Surg*. 1997;84(11):1493-1502.
- Rutgeerts P, Geboes K, Vantrappen G, Kerremans R, Coene-graets JL, Coremans G. Natural history of recurrent Crohn's disease at the ileocolonic anastomosis after curative surgery. *Gut*. 1984;25(6):665-672.
- Michelassi F, Balestracci T, Chappell R, Block GE. Primary and recurrent Crohn's disease. Experience with 1379 patients. *Ann Surg*. 1991;214(3):230-238.
- Greenstein AJ, Meyers S, Sher L, Heimann T, Aufses AH Jr. Surgery and its sequelae in Crohn's colitis and ileocolitis. *Arch Surg*. 1981;116(3):285-288.
- De Dombal FT, Watts JM, Watkinson G, Goligher JC. Local complications of ulcerative colitis: stricture, pseudopolypoid, and carcinoma of colon and rectum. *Br Med J*. 1966;1(5501):1442-1447.
- Edwards FC, Truelove SC. Course and prognosis of ulcerative colitis. *Gut*. 1964;32:1-22.
- Hommel DW, van Deventer SJ. Endoscopy in inflammatory bowel diseases. *Gastroenterology*. 2004;126(6):1561-1573.
- Li Y, Shen B. Successful endoscopic needle knife therapy combined with topical doxycycline injection of chronic sinus at ileal pouch-anal anastomosis. *Colorectal Dis*. 2012;14(4):e197-e199.
- Odze RD, Farraye FA, Hecht JL, Hornick JL. Long-term follow-up after polypectomy treatment for adenoma-like dysplastic lesions in ulcerative colitis. *Clin Gastroenterol Hepatol*. 2004;2(7):534-541.
- Rubin PH, Friedman S, Harpaz N, et al. Colonoscopic polypectomy in chronic colitis: conservative management after endoscopic resection of dysplastic polyps. *Gastroenterology*. 1999;117(6):1295-1300.
- Hurlstone DP, Sanders DS, Atkinson R, et al. Endoscopic mucosal resection for flat neoplasia in chronic ulcerative colitis: can we change the endoscopic management paradigm? *Gut*. 2007;56(6):838-846.
- Arora G, Mannalithara A, Singh G, et al. Risk of perforation from a colonoscopy in adults: a large population-based study. *Gastrointest Endosc*. 2009;69(3 pt 2):654-664.
- Rabeneck L, Paszat LF, Hilsden RJ, et al. Bleeding and perforation after outpatient colonoscopy and their risk factors in usual clinical practice. *Gastroenterology*. 2008;135(6):1899-1906.
- Lüning TH, Keemers-Gels ME, Barendregt WB, Tan AC, Rosman C. Colonoscopic perforations: a review of 30,366 patients. *Surg Endosc*. 2007;21(6):994-997.
- Iqbal CW, Chun YS, Farley DR. Colonoscopic perforations: a retrospective review. *J Gastrointest Surg*. 2005;9(9):1229-1235; discussion 1236.
- Cobb WS, Heniford BT, Sigmon LB, et al. Colonoscopic perforations: incidence, management, and outcomes. *Am Surg*. 2004;70(9):750-757; discussion 757-758.
- Korman LY, Overholt BF, Box T, Winker CK. Perforation during colonoscopy in endoscopic ambulatory surgical centers. *Gastrointest Endosc*. 2003;58(4):554-557.
- Araghizadeh FY, Timmcke AE, Opelka FG, Hicks TC, Beck DE. Colonoscopic perforations. *Dis Colon Rectum*. 2001;44(5):713-716.
- Levin TR, Zhao W, Conell C, et al. Complications of colonoscopy in an integrated health care delivery system. *Ann Intern Med*. 2006;145(12):880-886.
- Pantheris V, Haringsma J, Kuipers EJ. Colonoscopy perforation rate, mechanisms and outcome: from diagnostic to therapeutic colonoscopy. *Endoscopy*. 2009;41(11):941-951.
- Levine JS, Ahnen DJ. Clinical practice. Adenomatous polyps of the colon. *N Engl J Med*. 2006;355(24):2551-2557.

47. Thukkani N, Williams JL, Sonnenberg A. Epidemiologic characteristics of patients with inflammatory bowel disease undergoing colonoscopy. *Inflamm Bowel Dis*. 2011;17(6):1333-1337.
48. Carbonnel F, Lavergne A, Lémann M, et al. Colonoscopy of acute colitis. A safe and reliable tool for assessment of severity. *Dig Dis Sci*. 1994;39(7):1550-1557.
49. Koobatian GJ, Choi PM. Safety of surveillance colonoscopy in long-standing ulcerative colitis. *Am J Gastroenterol*. 1994;89(9):1472-1475.
50. Hardman KA, Manjunath S, Trash DB. Safety of colonoscopy. *J R Coll Physicians Lond*. 1995;29(5):398-400.
51. Terheggen G, Lanyi B, Schanz S, et al. Safety, feasibility, and tolerability of ileocolonoscopy in inflammatory bowel disease. *Endoscopy*. 2008;40(8):656-663.
52. Navaneethan U, Parasa S, Venkatesh PG, Trikudanathan G, Shen B. Prevalence and risk factors for colonic perforation during colonoscopy in hospitalized inflammatory bowel disease patients. *J Crohns Colitis*. 2011;5(3):189-195.
53. Navaneethan U, Kochhar G, Phull H, et al. Severe disease on endoscopy and steroid use increase the risk for bowel perforation during colonoscopy in inflammatory bowel disease patients. *J Crohns Colitis*. 2012;6(4):470-475.
54. Breysem Y, Janssens JF, Coremans G, Vantrappen G, Hendrickx G, Rutgeerts P. Endoscopic balloon dilation of colonic and ileo-colonic Crohn's strictures: long-term results. *Gastrointest Endosc*. 1992;38(2):142-147.
55. Thienpont C, D'Hoore A, Vermeire S, et al. Long-term outcome of endoscopic dilatation in patients with Crohn's disease is not affected by disease activity or medical therapy. *Gut*. 2010;59(3):320-324.
56. Couckuyt H, Gevers AM, Coremans G, Hiele M, Rutgeerts P. Efficacy and safety of hydrostatic balloon dilatation of ileocolonic Crohn's strictures: a prospective long-term analysis. *Gut*. 1995;36(4):577-580.
57. Singh VV, Dragonov P, Valentine J. Efficacy and safety of endoscopic balloon dilation of symptomatic upper and lower gastrointestinal Crohn's disease strictures. *J Clin Gastroenterol*. 2005;39(4):284-290.
58. East JC, Brooker JC, Rutter MD, Saunders BP. A pilot study of intrastricture steroid versus placebo injection after balloon dilatation of Crohn's strictures. *Clin Gastroenterol Hepatol*. 2007;5(9):1065-1069.
59. Di Nardo G, Oliva S, Passariello M, et al. Intralesional steroid injection after endoscopic balloon dilation in pediatric Crohn's disease with stricture: a prospective, randomized, double blind control trial. *Gastrointest Endosc*. 2010;72(6):1201-1208.
60. Raedler A, Peters I, Schreiber S. Treatment with azathioprine and budesonide prevents recurrence of ileocolonic stenoses [abstract]. *Gastroenterology*. 1997;112:A1067.
61. Thomas-Gibson S, Brooker JC, Hayward CM, Shah SG, Williams CB, Saunders BP. Colonoscopic balloon dilation of Crohn's strictures: a review of long-term outcomes. *Eur J Gastroenterol Hepatol*. 2003;15(5):485-488.
62. Navaneethan U, Shen B. Diagnosis and management of pouchitis and ileoanal pouch dysfunction. *Curr Gastroenterol Rep*. 2010;12(6):485-494.
63. Shen B, Lian L, Kiran RP, et al. Efficacy and safety of endoscopic treatment of ileal pouch strictures. *Inflamm Bowel Dis*. 2011;17(12):2527-2535.
64. Obusez EC, Lian L, Oberc A, Shen B. Multimedia article. Successful endoscopic wire-guided balloon dilatation of angulated and tight ileal pouch strictures without fluoroscopy. *Surg Endosc*. 2011;25(4):1306.
65. Shen B. Diagnosis and management of postoperative ileal pouch disorders. *Clin Colon Rectal Surg*. 2010;23(4):259-268.
66. Gomes OA, de Souza RR, Liberti EA. A preliminary investigation of the effects of aging on the nerve cell number in the myenteric ganglia of the human colon. *Gerontology*. 1997;43(4):210-217.
67. Hanani M, Fellig Y, Udassin R, Freund HR. Age-related changes in the morphology of the myenteric plexus of the human colon. *Auton Neurosci*. 2004;113(1-2):71-78.
68. Saunders BP, Fukumoto M, Halligan S, et al. Why is colonoscopy more difficult in women? *Gastrointest Endosc*. 1996;43(2 pt 1):124-126.
69. Chino A, Karasawa T, Urugami N, Endo Y, Takahashi H, Fujita R. A comparison of depth of tissue injury caused by different modes of electrosurgical current in a pig colon model. *Gastrointest Endosc*. 2004;59(3):374-379.
70. Savides TJ, See JA, Jensen DM, Jutabha R, Machicado GA, Hirabayashi K. Randomized controlled study of injury in the canine right colon from simultaneous biopsy and coagulation with different hot biopsy forceps. *Gastrointest Endosc*. 1995;42(3):573-578.
71. Van Gossum A, Cozzoli A, Adler M, Taton G, Cremer M. Colonoscopic snare polypectomy: analysis of 1485 resections comparing two types of current. *Gastrointest Endosc*. 1992;38(4):472-475.
72. Ramboer C, Verhamme M, Dhondt E, Huys S, Van Eygen K, Vermeire L. Endoscopic treatment of stenosis in recurrent Crohn's disease with balloon dilation combined with local corticosteroid injection. *Gastrointest Endosc*. 1995;42(3):252-255.
73. Dear KL, Hunter JO. Colonoscopic hydrostatic balloon dilatation of Crohn's strictures. *J Clin Gastroenterol*. 2001;33(4):315-318.
74. Brooker JC, Beckett CG, Saunders BP, Benson MJ. Long-acting steroid injection after endoscopic dilation of anastomotic Crohn's strictures may improve the outcome: a retrospective case series. *Endoscopy*. 2003;35(4):333-337.
75. Sabate JM, Villarejo J, Bouhnik Y, et al. Hydrostatic balloon dilatation of Crohn's strictures. *Aliment Pharmacol Ther*. 2003;18(4):409-413.
76. Morini S, Hassan C, Lorenzetti R, et al. Long-term outcome of endoscopic pneumatic dilatation in Crohn's disease. *Dig Liver Dis*. 2003;35(12):893-897.
77. Nomura E, Takagi S, Kikuchi T, et al. Efficacy and safety of endoscopic balloon dilation of Crohn's strictures. *Dis Colon Rectum*. 2006;49(10 suppl):s59-s67.
78. Ferlitsch A, Reinisch W, Püspök A, et al. Safety and efficacy of endoscopic balloon dilation for treatment of Crohn's disease strictures. *Endoscopy*. 2006;38(5):483-487.
79. Ajlouni Y, Iser JH, Gibson PR. Endoscopic balloon dilatation of intestinal strictures in Crohn's disease: safe alternative to surgery. *J Gastroenterol Hepatol*. 2007;22(4):486-490.
80. Mueller T, Rieder B, Bechtner G, et al. The response of Crohn's strictures to endoscopic balloon dilation. *Aliment Pharmacol Ther*. 2010;31(6):634-639.
81. Stienecker K, Gleichmann D, Neumayer U, et al. Long-term results of endoscopic balloon dilatation of lower gastrointestinal tract strictures in Crohn's disease: a prospective study. *World J Gastroenterol*. 2009;15(21):2623-2627.
82. Scimeca D, Mocciaro F, Cortone M, et al. Efficacy and safety of endoscopic balloon dilation of symptomatic intestinal Crohn's disease strictures. *Dig Liver Dis*. 2011;43(2):121-125.
83. Atreja A, Dwivedi S, Lashner B, Vargo JJ, Shen B. Short and long-term outcomes of endoscopic stricture dilation for primary and anastomotic strictures in patients with Crohn's disease. *Gastroenterology*. 2010;138(5 suppl 1):s528-s529.