

# ADVANCES IN ENDOSCOPY

Current Developments in Diagnostic and Therapeutic Endoscopy

Section Editor: John Baillie, MB ChB, FRCP

## Preliminary Data on the Nanopowder Hemostatic Agent TC-325 to Control Gastrointestinal Bleeding

Samuel A. Giday, MD, FACC  
Center for Digestive Health  
Orlando, Florida

**G&H** Why is a new hemostatic method needed for management of gastrointestinal bleeding? What limitations are associated with existing hemostatic modalities?

**SG** The ideal tool for any ailment is one which is easy to apply, durable, widely available, and cost-effective. None of the modalities currently used to control gastrointestinal bleeding fulfill these basic tenets. Existing endoscopic modalities for the management of gastrointestinal bleeding include thermal, nonthermal, and mechanical methods. Thermal hemostatic devices coagulate tissue as well as blood vessels, which leads to hemostasis. Although these devices are safe, complications such as perforation and precipitation of bleeding have been reported in up to 5% of cases. The principal nonthermal modality is injection therapy. This modality is particularly effective and safe when used as a combination therapy; most of the safety issues associated with this therapy arise when treating variceal bleeding. In these patients, severe local and systemic complications may develop, particularly when injecting sclerosants or glue. Clips are one of the most effective mechanical hemostatic agents currently used. The limitations of clips include the inability to be placed in tangential or difficult-to-reach areas, risk of developing perforations, and incompatibility with magnetic resonance imaging.

Endoscopic hemostatic treatment can be particularly difficult in patients with severe active bleeding and challenging anatomy, and technical expertise is often required. Preliminary data suggest that TC-325 (Hemospray, Cook

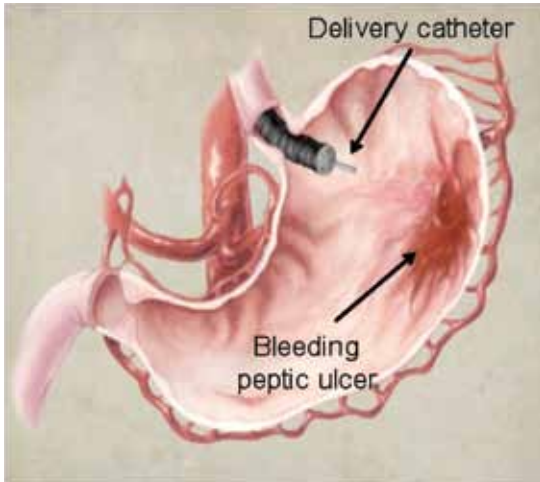
Endoscopy) may be able to overcome the limitations of existing endoscopic modalities for hemostasis in patients who present with severe arterial gastrointestinal bleeding (Figure 1).

**G&H** How does TC-325 stop bleeding?

**SG** TC-325 is a granular, mineral blend powder that achieves hemostasis by increasing the concentration of clotting factors, activating platelets, and forming a mechanical plug on the injured blood vessel. This highly absorptive powder is currently approved in Canada for management of nonvariceal upper gastrointestinal bleeding. When the powder comes into contact with moisture in the gastrointestinal tract, it becomes cohesive and adhesive, forming a stable mechanical barrier that adheres to and covers the bleeding site to achieve hemostasis. As the powder is not absorbed or metabolized by mucosal tissue, there is no risk of systemic toxicity. The covering formed by the powder separates from the intestinal wall and is naturally eliminated from the gastrointestinal tract.

**G&H** You and your colleagues recently conducted a study on the use of this agent in a porcine model. Could you discuss your findings?

**SG** Associates at various institutions and I wanted to determine whether TC-325 is safe and effective for management of severe arterial gastrointestinal bleeding. We created a gastrointestinal arterial bleeding model as follows: All animals underwent a sterile laparotomy with



**Figure 1.** Application of TC-325 using a delivery catheter passed through the accessory channel of an endoscope.

Reproduced from Giday SA, Kim Y, Krishnamurthy DM, et al. *Endoscopy*. 2011;43:296-299.

freeing of a 5-cm segment of the gastroepiploic vessels from the gastric wall. A 1-cm gastrotomy was performed adjacent to the free but intact blood vessel. The artery was then pushed through the gastrotomy and positioned so that it was exposed to the gastric lumen. The gastric incision was closed along with the abdominal wall via a standard closure technique. Intravenous heparin was then administered, with the target of achieving an activated clotting time that was twice the upper limit of normal. Upper endoscopy was performed, and the exposed vessel was located and incised with a needle knife until Forrest I pulsatile bleeding resulted.

The animals were randomized to either treatment (TC-325 via a modified delivery catheter) or sham. No control animals achieved hemostasis within the first hour compared to 100% of animals (5/5) in the treatment arm (mean, 13.8 minutes;  $P < .0079$ ). Durable hemostasis was achieved with no evidence of rebleeding after 1 hour and 24 hours in 80% of the treated animals (4/5) compared to none in the control group. None of the control animals survived more than 6 hours. In the treated animals, necropsy at 1 week revealed a healed gastrotomy without foreign body granuloma or embolization to the lung or brain.

**G&H** Have you conducted any other studies with this agent?

**SG** Our group then set out to assess the efficacy of this agent in humans in a prospective, single-arm, pilot clinical study. The study enrolled consecutive consenting adults

with confirmed peptic ulcer bleeding (Forrest 1a or 1b). These patients were stabilized before undergoing upper gastrointestinal endoscopy and application of TC-325 within 24 hours of hospital admission. Each patient was allowed up to 2 applications of TC-325 (not exceeding a total of 150 g). Recurrent bleeding was monitored postprocedure via a second-look endoscopy (72 hours post-treatment) and telephone (at 30 days). The rates of hemostasis, recurrent bleeding, mortality, need for surgical intervention, and treatment-related complications were assessed.

Immediate hemostasis was achieved in 95% of patients (19/20); 1 patient had a pseudoaneurysm requiring arterial embolization after failing TC-325 application as well as standard treatment (injection of epinephrine and placement of clips 3 times). Recurrent bleeding occurred in 2 patients within 72 hours (identified by a drop in hemoglobin level), with no active bleeding identified at the 72-hour endoscopy in either patient. There were no mortalities, major adverse events, or treatment-related or procedure-related serious adverse events reported during the 30-day follow-up period.

**G&H** What risks and limitations are associated with TC-325?

**SG** At this time, the use of this powder should be limited to nonvariceal gastrointestinal bleeding. No data exist regarding its use in patients with varices or significant systemic shunts. Up to now, TC-325 has been shown to be safe in patients with nonvariceal upper gastrointestinal bleeding with no evidence of systemic or local complications. It should not be used in patients where there is a possibility of shunting.

**G&H** Have there been any head-to-head studies comparing TC-325 with existing hemostatic modalities? If not, are any planned?

**SG** Although TC-325 appeared to be effective in the treatment of arterial upper gastrointestinal bleeding in both of our studies, it has not yet been compared to the currently available modalities. A direct comparison of these modalities in a randomized controlled trial would be very useful, and plans are currently underway to conduct such a trial.

**G&H** Apart from acute arterial bleeding, do you envision any other uses for TC-325 in the management of bleeding disorders of the gastrointestinal tract?

**SG** One can envision many gaps in gastrointestinal bleeding management that may be filled with this treat-

ment modality. As TC-325 can be applied to a wide area in a relatively short period of time, it can be used to stop bleeding over large surfaces, such as malignancy-related bleeding. It is also possible that TC-325 can be used as a stop-gap therapy to control acute bleeding so that definitive treatment can be implemented 2–3 days later when the patient's condition stabilizes. One can also envision application of the powder following endoscopic mucosal resection or polypectomy to help achieve hemostasis or to prevent bleeding (although these applications have not yet been studied). Other causes of gastrointestinal bleeding, such as gastric antral vascular ectasia and radiation-induced mucosal injury, may potentially be managed using TC-325 due to its safe and quick application to a wide area. Another potential area of application is in

patients who are coagulopathic or who are bleeding while on potent antiplatelet agents. In these scenarios, both thermal and nonthermal hemostatic methods can result in more bleeding.

### Suggested Reading

Giday SA, Kim Y, Krishnamurthy DM, et al. Longterm randomized controlled trial of novel nanopowder hemostatic agent (TC-325) for control of severe arterial upper gastrointestinal bleeding in a porcine model. *Endoscopy*. 2011;43:296-299.

Sung JJY, Luo D, Wu JCY, et al. Early clinical experience of the safety and effectiveness of Hemospray in achieving hemostasis in patients with acute peptic ulcer bleeding. *Endoscopy*. 2011;43:291-295.

Adler DG, Leighton JA, Davila RE, et al. ASGE guideline: The role of endoscopy in acute non-variceal upper-GI hemorrhage. *Gastrointest Endosc*. 2004;60:497-504.