

ADVANCES IN ENDOSCOPY

Current Developments in Diagnostic and Therapeutic Endoscopy

Section Editor: John Baillie, MB ChB, FRCP

Management of Acute Cholangitis

Patrick Mosler, MD, PhD
Division of Gastroenterology
University of Kentucky Medical Center
Lexington, Kentucky

G&H What is acute cholangitis?

PM Acute cholangitis is a systemic infectious disease characterized by acute inflammation and infection in the bile ducts resulting from a combination of biliary obstruction and bacterial growth in bile. Progressive biliary obstruction causes an increase in intraductal pressure, which eventually leads to cholangiovenous and cholangiolymphatic reflux. Translocation of bacteria into the bloodstream results in septicemia, an often fatal complication of acute cholangitis.

G&H What causes biliary obstruction?

PM Biliary obstruction can result from various etiologies, such as choledocholithiasis, benign stenoses (eg, in primary sclerosing cholangitis, as seen in Figure 1), malignant stenoses, biliary stent obstruction, strictured bilioenteric anastomoses, and parasitic colonization of the bile duct. It is not always clear how bacteria enter an obstructed biliary system, unless interventions such as surgery, endoscopic retrograde cholangiopancreatography (ERCP), or percutaneous transhepatic cholangiography (PTC) have been performed, resulting in the loss of the physiologic barrier between the bile duct and intestine (ie, biliary sphincterotomy, stent placement, surgical sphincteroplasty, bilioenteric anastomosis, and so on).

G&H What are the Charcot triad and the Pentad of Reynolds, and do they still have clinical importance for diagnosis of acute cholangitis?

PM Acute cholangitis was first described by Dr. Jean-Martin Charcot as “hepatic fever” in 1877. As a result, the

typical signs and symptoms of acute cholangitis—intermittent fever with chills, right upper quadrant pain, and jaundice—are known as the Charcot triad. The Pentad of Reynolds describes a more severe form of acute cholangitis in septic shock, with the addition of hypotension and confusion to the Charcot triad.

The diagnosis of acute cholangitis is based on a combination of typical clinical features, laboratory data, and imaging findings. Thus, knowledge of the Charcot triad as a typical clinical presentation of acute cholangitis is still of major importance.

Further confirmation of the diagnosis can then be made via laboratory data (ie, elevated C-reactive protein levels and/or leukocytosis) and abdominal imaging tests indicating biliary obstruction.

G&H What are the main goals when managing acute cholangitis?

PM Treatment of acute cholangitis is directed toward the 2 main etiologic components of the disease: biliary infection and obstruction. Therefore, treatment is comprised of systemic antibiotic therapy and biliary drainage procedures, with appropriate supportive care.

G&H When acute cholangitis is diagnosed or suspected, which antibiotics should be administered?

PM Antibiotic agents should be administered empirically to all patients with suspected acute cholangitis as early as possible. Blood and bile cultures should also be performed at the earliest opportunity.

The selection of an antibiotic agent should be based on potentially infecting bacteria, the severity of the disease, and the presence of comorbidities, such as hepatic or renal failure, patient allergies, local susceptibility patterns, and the patient’s history of antibiotic usage. Biliary penetration of antibiotic agents should be considered as well, though this is less important than the antibiotic agent’s efficacy against the suspected bacteria.

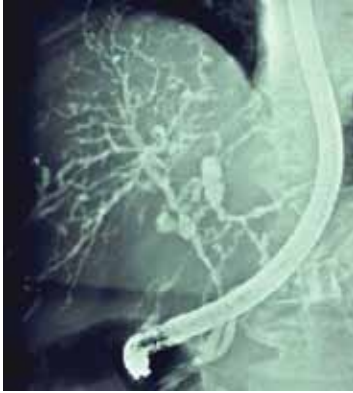


Figure 1. Primary sclerosing cholangitis (PSC). Retrograde cholangiography carries a significant risk of causing cholangitis in this setting, as the obstructed intrahepatic ducts cannot drain freely afterward. The first-line investigation of choice for PSC is now magnetic resonance cholangiopancreatography; endoscopic retrograde cholangiopancreatography should be reserved only for treatment of dominant extrahepatic bile duct strictures. (Image courtesy of John Baillie, MB ChB, FRCP, Wake Forest University Health Sciences Center, Winston-Salem, North Carolina.)

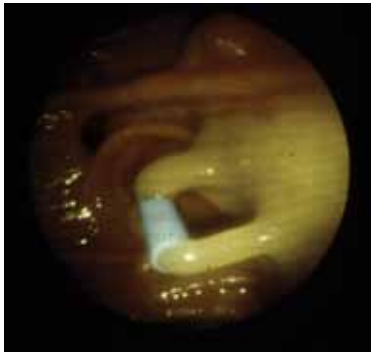


Figure 2. Fiberoptic endoscopic retrograde cholangiopancreatography view of pus exiting a plastic stent placed to decompress an obstructed bile duct. This is the preferred management when patients with acute cholangitis have severe coagulopathy, which is a contraindication to endoscopic sphincterotomy. (Image courtesy of John Baillie, MB ChB, FRCP, Wake Forest University Health Sciences Center, Winston-Salem, North Carolina.)

In addition, the clinical context should be considered when selecting an antibiotic, as it has been shown that anaerobic bacteria are found more frequently in severe cholangitis than in mild cases. Similarly, hospital-acquired cholangitis is often caused by multiple and/or resistant organisms, such as *Pseudomonas*, methicillin-

resistant *Staphylococcus aureus*, and vancomycin-resistant enterococci, whereas infection in community-acquired cases is mostly caused by a single species of an intestinal microorganism, such as *Escherichia coli*, *Klebsiella*, or *Enterococcus*.

The type and duration of antibiotic therapy should also be based on disease severity. For mild cases of acute cholangitis, 2–3 days of a penicillin/ β -lactamase inhibitor combination (ie, piperacillin/tazobactam or ampicillin/sulbactam) is usually sufficient. Moderate and severe disease should be treated for a minimum of 5–7 days with broad-spectrum agents, such as third- or fourth-generation cephalosporins or penicillin/ β -lactamase inhibitors. If the drug of first choice is ineffective, fluorquinolones and carbapenems are alternative agents.

The duration of treatment in all cases will ultimately depend on the response to treatment. If results of biliary or blood cultures become available, empirically initiated, broader-spectrum antibiotic regimens should be changed to narrower-spectrum agents.

G&H Can antibiotics be administered directly into the biliary tree to prevent or treat acute cholangitis?

PM As acute cholangitis is a systemic disease, antibiotic treatment should also be systemic and not limited to the bile duct. However, administration of antibiotics directly into the biliary tree (eg, in contrast media) may be useful for preventing acute cholangitis and sepsis secondary to bacterial contamination of sterile bile occurring as a complication of procedures such as ERCP. Only limited data are currently available to support this strategy, and systemic antibiotic regimens are still widely used in high-risk patients for prophylaxis during ERCP.

G&H What are the options for biliary drainage, particularly those involving ERCP and PTC?

PM Biliary obstruction is a persistent source of infection in acute cholangitis. Before biliary drainage procedures were readily available, the mortality of acute cholangitis was very high (up to 100%) with conservative therapy. This emphasizes the importance of biliary drainage in treatment of acute cholangitis.

Biliary drainage can be achieved via ERCP, PTC, endoscopic ultrasound (EUS)-guided drainage, or open surgical drainage. Open drainage is more invasive and has obvious disadvantages compared to endoscopic and percutaneous drains. Therefore, ERCP and PTC have become the most commonly performed methods for biliary drainage. Given the potential for serious complications with PTC (eg, intraperitoneal hemorrhage,

biliary peritonitis), the longer hospital stay associated with PTC, and the patient discomfort associated with a percutaneous catheter, ERCP is the procedure of choice whenever available. Options for endoscopic drainage during ERCP include biliary stent placement and nasobiliary drain placement, with or without biliary sphincterotomy (Figure 2).

If ERCP fails or is not available, PTC most frequently serves as a second-line alternative for biliary drainage. EUS-guided biliary drainage has recently been proven to be a feasible alternative to percutaneous transhepatic biliary drainage or surgery in centers with specific expertise when ERCP fails.

G&H What is the current mortality rate associated with acute cholangitis?

PM Advances in intensive care, antibiotic treatment regimens, and biliary drainage techniques have dramatically improved the mortality rate from over 50% prior to the 1970s to less than 7% in the 1980s. However, the mor-

tality rate due to cholangitis remains significant without appropriate management. Thus, early diagnosis of acute cholangitis and timely initiation of treatment is of utmost importance for a patient's prognosis. This particularly applies to elderly patients, who often present atypically, leading to a delay in diagnosis and treatment.

Suggested Reading

Mosler P. Diagnosis and management of acute cholangitis. *Curr Gastroenterol Rep.* 2011 Jan 5. [Epub ahead of print].

Sharma BC, Kumar R, Agarwal N, Sarin SK. Endoscopic biliary drainage by nasobiliary drain or by stent placement in patients with acute cholangitis. *Endoscopy.* 2005;37:439-443.

Salek J, Livote E, Sideridis K, Bank S. Analysis of risk factors predictive of early mortality and urgent ERCP in acute cholangitis. *J Clin Gastroenterol.* 2009;43:171-175.

Tokyo guidelines for the management of acute cholangitis and cholecystitis. Proceedings of a consensus meeting, April 2006, Tokyo, Japan. *J Hepatobiliary Pancreat Surg.* 2007;14:1-121.

Lee JG. Diagnosis and management of acute cholangitis. *Nat Rev Gastroenterol Hepatol.* 2009;6:533-541.

Agarwal N, Sharma BC, Sarin SK. Endoscopic management of acute cholangitis in elderly patients. *World J Gastroenterol.* 2006;12:6551-6555.