

Mucosal Schwann Cell Hamartoma of the Colon in a Patient with Ulcerative Colitis

Brittney Neis, BA¹
 Phil Hart, MD¹
 Vishal Chandran, MBBS²
 Sunanda Kane, MD, MSPH¹

¹Division of Gastroenterology and Hepatology and

²Department of Pathology, Mayo Clinic, Rochester, Minnesota

Case Report

A man age 59 years with ulcerative colitis–associated primary sclerosing cholangitis presented to the clinic for his annual colonoscopy with surveillance biopsies. The patient was receiving oral mesalamine, and the primary sclerosing cholangitis was in clinical remission at that time. The patient did not have a history of colonic dysplasia, but adenomatous colonic polyps were diagnosed the previous year. There was no personal or family history of neurofibromatosis type 1 (NF-1), Cowden syndrome, or multiple endocrine neoplasia type 2b (MEN 2b). At the time of colonoscopy, the ileal and colonic mucosa appeared to be normal. A 3-mm sigmoid polyp was removed by a cold biopsy, and additional biopsies were obtained from the surrounding mucosa.

Histologically, hematoxylin and eosin stains showed a polypoid fragment of colonic mucosa that had a bland spindle cell proliferation with elongated nuclei, abundant dense eosinophilic cytoplasm, and inconspicuous cell borders within the lamina propria (Figure 1). No nuclear pleomorphism or mitotic activity was present. Immunostaining showed that the spindle cells were strongly S-100–positive (Figure 2) and negative for Claudin-1, epithelial membrane antigen (EMA), CD117, and CD34 (the immunophenotype for Schwann cells). There was no dysplasia in the mucosa surrounding the polypectomy site. The final diagnosis was mucosal Schwann cell hamartoma.

The patient was counseled to continue annual colonoscopies with surveillance biopsies in light of his inflammatory bowel disease (IBD).

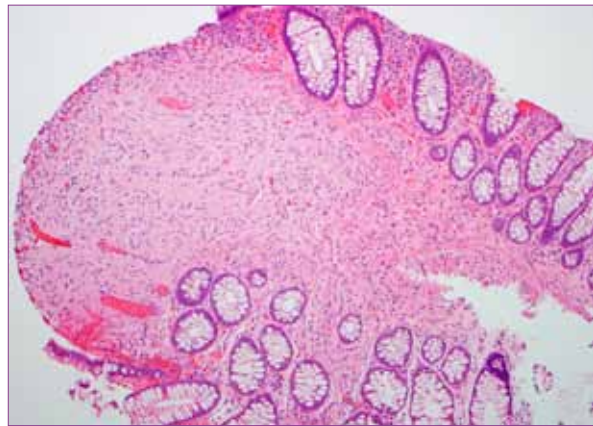


Figure 1. Histologic features of a mucosal Schwann cell hamartoma. A low-power view of hematoxylin and eosin–stained colonic mucosa demonstrated bland spindle cell proliferation with elongated nuclei and dense eosinophilic cytoplasm, which is consistent with Schwann cell proliferation.

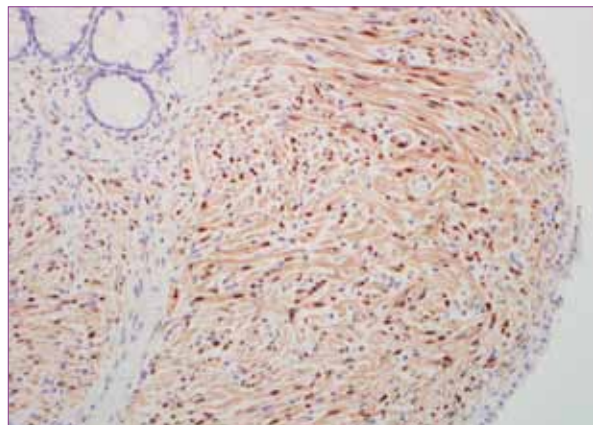


Figure 2. Immunohistochemical features of a mucosal Schwann cell hamartoma. A high-power view using the S-100 immunostain showed strongly positive staining spindle cells. Other stains for Claudin-1, epithelial membrane antigen, CD117, and CD34 were negative.

Address correspondence to:

Dr. Sunanda Kane, Division of Gastroenterology and Hepatology, Mayo Clinic,
 200 First Street SW, Rochester, MN 55905; Tel: 507-284-0959; Fax: 507-284-0538;
 E-mail: Kane.Sunanda@mayo.edu

Discussion

Herein, we report the first case of a mucosal Schwann cell hamartoma in a patient with ulcerative colitis. It is unclear whether the patient's underlying IBD contributed to the development of this lesion, but the patient's clinical course had been uncomplicated to date, and the natural history of this lesion is typically benign.

Benign nerve sheath tumors are not uncommon in the skin or soft tissue; however, involvement of the gastrointestinal tract is uncommon. Although there are common histologic features of neural tumors, the immunostaining pattern is necessary to differentiate them from each other. The mucosal Schwann cell hamartoma is one variant of these tumors that has been recently described.¹⁻³

The differential diagnoses of neural lesions of the colon include schwannomas, neurofibromas, perineuriomas, ganglioneuromas, and granular cell tumors.¹ Of these lesions, neurofibromas and mucosal neuromas are associated with NF-1 and MEN 2b, respectively.⁴ Additionally, ganglioneuromas have been associated with Cowden syndrome.⁵ In 2009, the term mucosal Schwann cell hamartoma was proposed to describe polypoid lesions that are histologically characterized by neural proliferation in the absence of ganglion cells and occur in the absence of one of the aforementioned inherited syndromes.¹

Gibson and Hornick's series of 26 cases is the largest published series of mucosal Schwann cell hamartomas to date and provides several helpful clinicopathologic associations.¹ Most of the polyps in this series were small, ranging from 1–6 mm (mean, 2.5 mm), and were predominantly distributed in the left colon (n=22), with the greatest concentration in the rectosigmoid colon (n=15). Histologically, the polyps displayed diffuse proliferation of spindle cells in the lamina propria that was not clearly discernible when compared with 5 neurofibromas. However, immunohistochemistry showed strong staining for S-100 in almost all cells in the Schwann cell hamartomas and a paucity of axons on neurofilament protein (NFP) staining. In contrast, the neurofibromas had less intense staining for S-100 and a higher concentration of NFP-positive axons. Importantly, at follow-up, recurrent neural polyps did not develop in any of the patients. Since Gibson and Hornick's initial description of mucosal Schwann cell hamartomas, 2 additional cases have been reported, each with similar clinical profiles, including a benign natural history.¹⁻³

The differentiation in our patient's lesion from other diagnostic considerations was dependent on pathologic analyses, including immunohistochemistry. Distinguishing schwannomas from Schwann cell hamartomas is often challenging in that both types of lesions are diffusely and strongly positive for S-100; however, schwannomas are also notable for the presence of

peripheral cuff-like lymphoid aggregates with germinal centers and are composed exclusively of Schwann cells.⁶ Additionally, schwannomas are typically found in the stomach and are rarely colonic.⁷

Neurofibromas, which are more commonly found in patients with NF-1, tend to occur in the stomach and jejunum and often exhibit scattered axons.⁸ Hochberg and colleagues reported that 30 (77%) of 39 patients with a gastrointestinal tumor had a neurofibroma; the others had leiomyomas.⁸ Therefore, when a colonic neurofibroma is found, NF-1 should be considered; however, the easily recognizable cutaneous neurofibromas make it unlikely that this would be the primary clinical presentation. Immunohistochemically, cells are positive for CD34, which helps differentiate them from schwannomas.⁷

Perineuriomas can show entrapment of colonic crypts similar to that of mucosal Schwann cell hamartomas but are S-100–negative, EMA–positive, and variably express the tight junction-associated protein Claudin-1.⁹ Clinically, these lesions can present as intestinal masses in addition to colonic polyps, but, fortunately, the prognosis remains benign.

Ganglioneuromas are composed of ganglion cells, nerve fibers, and axons, which are readily detectable with S-100 and NFP staining. They have been described in multiple inherited genetic syndromes, including Cowden syndrome, NF-1, and MEN 2b.^{5,10} However, in a retrospective study of 28 patients in whom a ganglioneuroma polyp was diagnosed, no recurrent tumor or finding consistent with a genetic syndrome developed in any of the 16 patients who had a mean 8-year follow-up.¹⁰ Instead, these disease associations were seen in those patients with diffuse ganglioneuromatosis, described as poorly demarcated intramural or transmural proliferations.

One final consideration, and a more common type of mesenchymal tumor, is the gastrointestinal stromal tumor (GIST). The ability to distinguish a GIST from a Schwann cell hamartoma is critical because, unlike neural tumors, GISTs have malignant potential. Moreover, there is a clear association between GISTs and NF-1.¹¹ GISTs are also often S-100–positive, but, importantly, they have characteristic antibodies to c-Kit/CD117, which distinguish them from mucosal Schwann cell hamartomas.

In conclusion, we describe a patient with ulcerative colitis who was incidentally noted to have a mucosal Schwann cell hamartoma at the time of surveillance colonoscopy. To our knowledge, this is the first description of this mucosal abnormality in a patient with IBD. Clinically, this lesion has a benign natural history and no apparent association with one of the inherited polyposis syndromes. The differential diagnosis of neural tumors is broad, and accurate diagnosis of a mucosal Schwann cell hamartoma is dependent on histologic demonstration of a lack of axons and immunohistochemically by strong staining for S-100 protein.

References

1. Gibson JA, Hornick JL. Mucosal Schwann cell "hamartoma": clinicopathologic study of 26 neural colorectal polyps distinct from neurofibromas and mucosal neuromas. *Am J Surg Pathol*. 2009;33:781-787.
2. Pasquini P, Baiocchi A, Falasca L, et al. Mucosal Schwann cell "hamartoma": a new entity? *World J Gastroenterol*. 2009;15:2287-2289.
3. Rocco EG, Iannuzzi F, Dell'Era A, et al. Schwann cell hamartoma: case report. *BMC Gastroenterol*. 2011;11:68.
4. Schreiber IR, Baker M, Amos C, McGarrity TJ. The hamartomatous polyposis syndromes: a clinical and molecular review. *Am J Gastroenterol*. 2005;100:476-490.
5. Stanich PB, Owens VL, Sweetser S, et al. Colonic polyposis and neoplasia in Cowden syndrome. *Mayo Clin Proc*. 2011;86:489-492.
6. Hou YY, Tan YS, Xu JF, et al. Schwannoma of the gastrointestinal tract: a

clinicopathological, immunohistochemical and ultrastructural study of 33 cases. *Histopathology*. 2006;48:536-545.

7. Miettinen M, Shekitka KM, Sobin LH. Schwannomas in the colon and rectum: a clinicopathologic and immunohistochemical study of 20 cases. *Am J Surg Pathol*. 2001;25:846-855.

8. Hochberg FH, Dasilva AB, Galdabini J, Richardson EP Jr. Gastrointestinal involvement in von Recklinghausen's neurofibromatosis. *Neurology*. 1974;24:1144-1151.

9. Hornick JL, Fletcher CD. Intestinal perineuromas: clinicopathologic definition of a new anatomic subset in a series of 10 cases. *Am J Surg Pathol*. 2005;29:859-865.

10. Shekitka KM, Sobin LH. Ganglioneuromas of the gastrointestinal tract. Relation to Von Recklinghausen disease and other multiple tumor syndromes. *Am J Surg Pathol*. 1994;18:250-257.

11. Ho MY, Blanke CD. Gastrointestinal stromal tumors: disease and treatment update. *Gastroenterology*. 2011;140:1372-1376.e2.

Review

Mucosal Schwann Cell Hamartoma in Ulcerative Colitis: Diagnosis and Clinical Relevance

Welmoed K. van Deen, MD^{1,2}

Daniel W. Hommes, MD, PhD¹

¹Center for Inflammatory Bowel Diseases, University of California at Los Angeles, Los Angeles, California;

²Department of Gastroenterology and Hepatology, Leiden University Medical Center, Leiden, The Netherlands

The term Schwann cell hamartoma was first proposed in 2009 by Gibson and Hornick to describe a group of lesions that were previously referred to as neurofibromas or neuromas.¹ Schwann cell hamartomas are a group of colorectal polyps that are composed of pure Schwann cell proliferation confined to the lamina propria. Endoscopically, Schwann cell hamartomas appear as sessile polyps in the colorectum. Histologically, poorly circumscribed lesions with spindle cell proliferation are observed. Cells stain strongly positive for S-100. Importantly, these lesions are not associated with inherited syndromes, such as neurofibromatosis type 1 (NF-1) and multiple endocrine neoplasia type 2b (MEN 2b), in contrast to several other peripheral nerve tumors.¹ Since Gibson and Hornick described Schwann cell hamartoma, several case reports have been published.¹⁻⁴ The clinical course seems to be benign, as no recurrent lesions have been reported.

Differential Diagnosis

Different mesenchymal and neural tumors need to be considered in the differential diagnosis. Many different gastrointestinal mesenchymal mucosal and submucosal polyps have been described in the literature; however, many still remain unclassified. Gastrointestinal stromal tumors are also included in the differential diagnosis, but when they invade the mucosa, they are usually large and malignant, and they generally present as a mass with or without mucosal ulceration rather than as a polyp.^{5,6} To diagnostically classify the lesion, immunohistochemical staining of the tissue is undoubtedly necessary.

A few more common lesions that should be considered in the differential diagnosis of a Schwann cell hamartoma and that can present as a mucosal polyp include a perineuroma, which consists of spindle cells but stains uniformly negative for S-100; a ganglioneuroma, which consists of S-100–positive spindle cells admixed with ganglion cells; a granular cell tumor, which consists of S-100–positive cells intervened by fibrous septae; and a leiomyoma, which is a well-circumscribed, smooth muscle cell tumor.⁶

Several more peripheral nerve tumors also can be considered in the differential diagnosis of Schwann cell hamartomas. Schwannomas are encapsulated benign peripheral nerve tumors consisting of S-100–positive cells. Neurofibromas are tumors usually originating from small superficial nerves that are composed of elongated cells intermixed with collagen bundles or mucin, and not all of the compounds stain positive for S-100. Malignant peripheral nerve sheath tumors are spindle cell sarcomas that most commonly arise from large nerve trunks.⁷ A traumatic neuroma, which is a non-neoplastic nerve tumor that develops due to a hyperproliferative response to chronic friction or irritation, trauma, or surgery is another type of peripheral nerve lesion. Traumatic neuromas consist of proliferating fascicles with disrupted axons that are less well myelinated than those in the parent nerve.^{7,8} Mucosal neuromas are lesions that are most commonly found

Address correspondence to:

Dr. Welmoed K. van Deen, 10945 Le Conte Avenue #2338C, Los Angeles, CA 90095; Tel: 310-206-5785; Fax: 310-206-9906; E-mail: wvandeend@mednet.ucla.edu

on the tongue and lips and are strongly associated with MEN 2b.⁹ In conclusion, the most important consideration in the differential diagnosis should be the exclusion of lesions that are malignant or premalignant and that are associated with inherited syndromes.

Neis and colleagues describe a case of mucosal Schwann cell hamartoma in a patient age 59 years with ulcerative colitis (UC) and primary sclerosing cholangitis.⁴ This is the first case of mucosal Schwann cell hamartoma in a patient with UC reported in the literature. Whether the underlying UC contributed to the development of the lesion is unclear.⁴

Inflammation and Immunosuppression

UC is within the spectrum of inflammatory bowel disease (IBD). IBD has been associated with the development of colorectal carcinoma and lymphoma, among other malignancies. Two main links associated with carcinogenesis exist between IBD and tumor formation: chronic inflammation and the use of immunosuppressive agents.¹⁰

The mechanisms that promote carcinogenesis in an inflammatory environment are related to inflammation-induced changes in cytokines, growth factors, reactive oxygen species, and miRNA signatures, among other cellular processes.^{11,12} As a consequence, both genetic and epigenetic changes take place that can eventually result in cancer development.¹¹ Systemic but also local chronic inflammation can promote carcinogenesis. The former has been described in rheumatoid arthritis, for example.¹⁰ In IBD, however, systemic inflammation does not seem to play a role; rather, chronic local inflammation may be associated with carcinogenesis in this disease entity.¹⁰

In addition, immunosuppressive medication might facilitate the escape of tumor cells from the immune system and support the growth of latent tumors. Also, immunosuppressive agents can diminish antiviral response against carcinogenic viruses, thereby creating, for example, a theoretical increased risk of cervical cancer in a woman positive for human papillomavirus. A clear association between the use of immunosuppressive agents and carcinogenesis has been shown in patients who have received an organ transplant.¹⁰ Whether this association is also relevant in patients with IBD remains very controversial.

In general, most autoimmune diseases are associated with an increased risk of cancer. Associations between several autoimmune diseases of the nervous system and carcinogenesis have been described as well. Patients with multiple sclerosis, a chronic autoimmune disorder targeting the myelin sheaths of nerves in the central nervous system, are at increased risk for the development of brain tumors. Interestingly, these patients seem to have a decreased risk of solid tissue tumor development. For other autoimmune disorders of the peripheral nervous system, such as Guillain-

Barré syndrome, myasthenia gravis, and Lambert-Eaton syndrome, a converse association has been described. In these diseases, the autoimmunity seems to be a paraneoplastic phenomenon.¹² Whether chronic inflammation might influence the development of peripheral nerve tissue neoplasms is not clear. As mentioned above, traumatic neuromas have been described at sites of tissue injury, and the formation of these neuromas seems to be mediated by the processes of continuous inflammation and nerve regeneration. These traumatic neuromas, however, are not true neoplasms but hyperplastic regenerative responses of injured nerves.^{7,8} Whether development of mucosal Schwann cell hamartoma can be mediated by inflammation remains unknown as well.

Conclusion

The case presentation by Neis and colleagues elegantly illustrates the importance of recognizing mucosal polyps that have origins that differ from the more common adenomatous lesions found in gastrointestinal mucosa.⁴ Many mucosal lesions of mesenchymal and neurogenic origin are benign; however, it is important to identify malignant and premalignant lesions and to define lesions associated with inherited syndromes, such as NF-1. Whether the development of mucosal Schwann cell hamartoma can be triggered by inflammation in IBD remains unclear. No malignant transformation or recurrence of this lesion has been reported; therefore, it seems reasonable to forego extra interventions following diagnosis.

References

- Gibson JA, Hornick JL. Mucosal Schwann cell "hamartoma": clinicopathologic study of 26 neural colorectal polyps distinct from neurofibromas and mucosal neuromas. *Am J Surg Pathol.* 2009;33:781-787.
- Rocco EG, Iannuzzi F, Dell'Era A, et al. Schwann cell hamartoma: case report. *BMC Gastroenterol.* 2011;11:68.
- Pasquini P, Baiocchi A, Falasca L, et al. Mucosal Schwann cell "hamartoma": a new entity? *World J Gastroenterol.* 2009;15:2287-2289.
- Neis B, Hart P, Chandran V, Kane S. Mucosal Schwann cell hamartoma of the colon in a patient with ulcerative colitis. *Gastroenterol Hepatol (N Y).* 2013;9:183-185.
- Stamatikos M, Douzinas E, Stefanaki C, et al. Gastrointestinal stromal tumor. *World J Surg Oncol.* 2009;7:61.
- Rittershaus AC, Appelman HD. Benign gastrointestinal mesenchymal BUMPS: a brief review of some spindle cell polyps with published names. *Arch Pathol Lab Med.* 2011;135:1311-1319.
- Woertler K. Tumors and tumor-like lesions of peripheral nerves. *Semin Musculoskelet Radiol.* 2010;14:547-558.
- Li Q, Gao EL, Yang YL, Hu HY, Hu XQ. Traumatic neuroma in a patient with breast cancer after mastectomy: a case report and review of the literature. *World J Surg Oncol.* 2012;10:35.
- Moline J, Eng C. Multiple endocrine neoplasia type 2: an overview. *Genet Med.* 2011;13:755-764.
- Beaugerie L. Inflammatory bowel disease therapies and cancer risk: where are we and where are we going? *Gut.* 2012;61:476-483.
- Chiba T, Marusawa H, Ushijima T. Inflammation-associated cancer development in digestive organs: mechanisms and roles for genetic and epigenetic modulation. *Gastroenterology.* 2012;143:550-563.
- Franks AL, Slansky JE. Multiple associations between a broad spectrum of autoimmune diseases, chronic inflammatory diseases and cancer. *Anticancer Res.* 2012;32:1119-1136.