

# Mimicry and Deception in Inflammatory Bowel Disease and Intestinal Behçet Disease

Erika L. Grigg, MD, Sunanda Kane, MD, MSPH, and Seymour Katz, MD

Dr. Grigg is a Gastroenterology Fellow at Georgia Health Sciences University in Augusta, Georgia. Dr. Kane is a Professor of Medicine in the Division of Gastroenterology and Hepatology at the Mayo Clinic in Rochester, Minnesota. Dr. Katz is a Clinical Professor of Medicine at Albert Einstein College of Medicine in Great Neck, New York.

Address correspondence to:

Dr. Seymour Katz

Albert Einstein College of Medicine

1000 Northern Boulevard

Great Neck, NY 11021;

Tel: 516-466-2340;

Fax: 516-829-6421;

E-mail: seymourkatz.md@gmail.com

**Abstract:** Behçet disease (BD) is a rare, chronic, multisystemic, inflammatory disease characterized by recurrent oral aphthous ulcers, genital ulcers, uveitis, and skin lesions. Intestinal BD occurs in 10–15% of BD patients and shares many clinical characteristics with inflammatory bowel disease (IBD), making differentiation of the 2 diseases very difficult and occasionally impossible. The diagnosis of intestinal BD is based on clinical findings—as there is no pathognomonic laboratory test—and should be considered in patients who present with abdominal pain, diarrhea, weight loss, and rectal bleeding and who are susceptible to intestinal BD. Treatment for intestinal BD is similar to that for IBD, but overall prognosis is worse for intestinal BD. Although intestinal BD is extremely rare in the United States, physicians will increasingly encounter these challenging patients in the future due to increased immigration rates of Asian and Mediterranean populations.

Behçet disease (BD) is a rare, chronic, recurrent, multisystemic, inflammatory disease that was first described by the Turkish dermatologist Hulusi Behçet in 1937 as a syndrome with oral and genital ulcerations and ocular inflammation.<sup>1,2</sup>

## Prevalence

BD is more common and severe in East Asian and Mediterranean populations. The prevalence of BD is greatest in Turkey (80–370 cases per 100,000 individuals) followed by Asia and the Middle East (13.5–20 cases per 100,000 individuals).<sup>3</sup> In the United States, the prevalence of BD is only 1–2 cases per 1 million individuals.<sup>4</sup>

BD typically affects patients 20–40 years of age and is somewhat more common in Japanese and Korean women and Middle Eastern men.<sup>1</sup> Gastrointestinal (GI) manifestations of BD, also known as intestinal Behçet disease or entero-Behçet disease, occur in 0–60% of BD patients, depending on the affected population.<sup>3</sup> Intestinal BD

## Keywords

Intestinal Behçet disease, inflammatory bowel disease, Behçet disease, Crohn's disease, ulcerative colitis

is more common among patients in the Far East, particularly Japan, while it is less common in the Middle East.<sup>5</sup> Intestinal symptoms affect approximately one third of BD patients in the United States.<sup>6</sup>

## Etiology

The underlying etiology of BD is unknown, but genetic and environmental factors are believed to play a role.<sup>1</sup> BD may represent aberrant immune activity triggered by exposure to a specific agent (infectious or environmental) in patients with an underlying genetic predisposition.<sup>7</sup> In addition to being associated with increased disease severity, human leukocyte antigen (HLA)-B51 is the genetic factor most strongly associated with BD; however, this antigen accounts for less than 20% of the genetic risk.<sup>8</sup> Recent studies have identified common variants in interleukin (IL)-10, IL-19, and the IL-23R–IL-12B2 locus, all of which predispose individuals to BD.<sup>8,9</sup> Reduced IL-10 expression has been linked to inflammation.<sup>8</sup> Variants in the IL-10 region have also been associated with ulcerative colitis (UC) and Crohn's disease (CD).<sup>8,9</sup> HLA-A26 is another allele associated with BD in certain populations.<sup>10</sup> Polymorphisms of certain non-HLA genes have also been associated with BD.<sup>11</sup>

Microbial infections suspected in the development of BD include herpes simplex virus-1, which has been demonstrated in genital and intestinal ulcers but not in oral ulcers.<sup>7</sup> *Streptococcus sanguis* and its antibodies are more frequently found in the oral flora and serum of patients with BD than in non-BD patients.<sup>1</sup> Parvovirus B19 DNA levels are higher in nonulcerative skin lesions of BD patients than in ulcerative skin lesions or compared to non-BD patients.<sup>12</sup> However, no infectious etiology has been proven to be causative to date.<sup>1</sup>

Genetic factors alone do not predict the likelihood of developing BD. A study of 2 sets of discordant twins and 1 set of concordant twins reinforced the importance of both genetic and environmental factors in the development of BD.<sup>13</sup> Smoking is an important factor in BD; smoking cessation may cause flares in oral aphthous and/or genital ulcers.<sup>14</sup> The protective effect of smoking in BD is similar to that seen in UC.<sup>14</sup>

## Pathogenesis

The exact etiology and pathogenesis of BD are unknown, but they are thought to be immune-mediated in genetically susceptible individuals.<sup>15</sup> Heat shock proteins (HSPs) of microorganisms may trigger a cross-reactive autoimmune response in B and T cells in patients with BD. HSP65 is abundantly expressed in epidermal regions of active mucocutaneous ulcers and erythema

nodosum in BD.<sup>5</sup> Both the adaptive and innate immune systems are activated in BD.<sup>7</sup>

BD is characterized by vascular injury, elevated neutrophil function, and an autoimmune reaction. The presence of vasculitis in or near BD lesions helps to confirm diagnosis of the disease. These lesions have a predominance of neutrophilic infiltrations in the absence of an infectious etiology. Tumor necrosis factor (TNF)- $\alpha$ , IL-1 $\beta$ , and IL-8 levels may be elevated in BD patients.<sup>1</sup> Serum levels of IL-12 and TNF- $\alpha$  often correlate with disease activity.<sup>16</sup>

## Clinical Manifestations

The clinical picture of BD is heterogeneous, and there appear to be various clusters of disease expression, such as oral and genital ulcers, erythema nodosum, superficial thrombophlebitis, acne, and arthritis.<sup>17</sup> Spondyloarthropathy and mucocutaneous and ocular symptoms are most severe during the first several years after diagnosis, whereas central nervous system and large-vessel vasculitides usually present later in the disease course. Oral ulcerations are the initial manifestation of BD in 90% of patients; however, oral ulcerations are seen in all patients at some point during their disease course, typically preceding diagnosis of the disease by 6–7 years.<sup>18</sup> Oral lesions typically heal without scarring within 10 days.<sup>1</sup> Genital ulcers occur in over 75% of patients; these ulcers result in scarring (unlike oral ulcers) and heal within 30 days (provided that a secondary infection does not develop).<sup>1,18</sup>

## Intestinal Manifestations

The most common intestinal symptoms of BD are diarrhea (bloody or nonbloody), nausea, vomiting, and abdominal pain.<sup>3,19</sup> Other symptoms include gastrointestinal bleeding (GIB) and weight loss.<sup>20</sup> It may be extremely difficult to distinguish intestinal BD from inflammatory bowel disease (IBD) due to similarities in their intestinal and extraintestinal manifestations and pathologic findings.<sup>1</sup> Intestinal BD often requires surgical intervention due to complications from perforations, fistulae formation, and massive GIB, which occur in up to 50% of patients.<sup>5</sup> Patients with refractory colonic complications are often believed to have both intestinal BD and IBD.

Intestinal symptoms usually appear 4–6 years after the onset of oral ulcers.<sup>3</sup> In complicated cases of intestinal BD, diagnosis has taken up to 7 years.<sup>21</sup> Intestinal ulcers are often resistant to medical therapy and frequently recur after surgical therapy.<sup>3</sup>

Although the ileocecal region is most commonly affected in intestinal BD, other regions of the GI system

**Table 1.** Gastrointestinal Manifestations of Behçet Disease

Anatomic site(s)	Gastrointestinal manifestation(s)
Esophagus	Ulcers,* esophagitis, fistulae, strictures, varices
Stomach, small intestine, colon	Ulcers*
Anal/rectal region	Ulcers,* fistulae, abscesses, proctitis, fissures
Liver	Budd-Chiari syndrome (acute, subacute, or chronic), fatty liver disease, hepatomegaly, congestion, cirrhosis
Spleen	Splenomegaly, congestion
Pancreas	Acute pancreatitis

\*Ulcers are typically round, deep, and well demarcated, regardless of their location.

Adapted from Bayraktar Y, Ozaslan E, Van Thiel DH.<sup>3</sup>

may also be involved, including the esophagus, stomach, duodenum, jejunum, and colon.<sup>3</sup> Rectal involvement is extremely rare and occurs in less than 1% of patients.<sup>6,22</sup> Table 1 lists the different types of lesions that can be seen throughout the GI tract. Esophageal involvement is seen in 2–11% of cases, but these figures may be underestimated.<sup>3</sup> In order to differentiate esophageal lesions associated with BD from those associated with other conditions, biopsies and cultures must be obtained. Esophageal lesions respond well to high-dose corticosteroid (CS) therapy.<sup>6,23</sup> The stomach is the least commonly affected part of the GI tract.<sup>3</sup> Duodenal BD presents with aphthous ulcers, which are resistant to medical therapy; however, unlike typical chronic peptic ulcers, duodenal deformity is not seen, and biopsies of the ulcers may reveal microthrombi of the mucosal vessels.<sup>3</sup>

BD can also affect the liver, pancreas, and spleen.<sup>3</sup> Patients may present with hepatomegaly, ascites, lower extremity edema, and abdominal and/or thoracic wall varices.<sup>3</sup> Patients develop extensive intrahepatic and abdominal collaterals in order to drain hepatic blood due to occlusion of hepatic veins and the hepatic inferior vena cava.<sup>3</sup> Budd-Chiari syndrome is an important extraintestinal manifestation that carries a grave prognosis.<sup>24</sup> Splenic involvement has been noted on autopsy in up to 22% of patients with BD.<sup>25</sup>

### Assessment of Disease Activity

In every disease, having an objective means of assessing disease activity is crucial for determining the best therapeutic approach and for assessing response to treatment.

**Table 2.** Disease Activity Index for Intestinal Behçet Disease

Clinical feature	Score (points)
General well-being over the past week	
Well	0
Fair	10
Poor	20
Very poor	30
Terrible	40
Fever	
<38°C	0
≥38°C	10
Extraintestinal manifestations	5 per type of manifestation*
Abdominal pain over the past week	
None	0
Mild	20
Moderate	40
Severe	80
Abdominal mass	
None	0
Palpable mass	10
Abdominal tenderness	
None	0
Mildly tender	10
Moderately or severely tender	20
Intestinal complications	10 per type of complication**
Number of liquid stools over the past week	
0	0
1–7	10
8–21	20
22–35	30
≥36	40

\*Five points are added for each type of the following manifestations: oral ulcers, genital ulcers, eye lesions, skin lesions, or arthralgia; 15 points are added for each of the following: vascular involvement or central nervous system involvement. \*\*Such as a fistula, perforation, abscess, or intestinal obstruction.

Adapted from Cheon JH, Han DS, Park JY, et al.<sup>4</sup>

In 2011, Cheon and associates developed a Disease Activity Index for Intestinal BD (DAIBD; Table 2).<sup>4</sup> Previously, intestinal symptoms had been assessed using the Crohn’s Disease Activity Index, which had been criticized as cumbersome for use in practice. Diarrhea is a major symptom in CD, whereas abdominal pain is more important in intestinal BD.<sup>4</sup> The DAIBD is a relatively simple, 8-index scoring system that assesses clini-

cal features that have been present over the preceding 7 days; it does not require laboratory data or endoscopic findings, which makes for easier use in the outpatient setting.<sup>4</sup> The creators of the DAIBD did not include the symptom of massive GI hemorrhage, which is occasionally fatal, due to its relatively uncommon occurrence during the study period.<sup>4</sup>

## Diagnostic Criteria

BD has many diverse clinical features and is often extremely difficult to diagnose. The diagnosis of BD should be considered when a patient has 2–3 of the following symptoms: painful, recurrent mouth ulcers; genital ulcers; inflamed eyes or joints; skin lesions; thrombophlebitis; or a family history of BD. Referral to a specialist or clinician who is experienced in BD is recommended.<sup>15</sup>

In 1990, the International Study Group (ISG) for BD established a set of diagnostic criteria (Table 3).<sup>26</sup> The ISG criteria for BD are not a perfect tool and cannot replace clinical judgment, but they are helpful for reminding clinicians of the most important diagnostic features of BD.<sup>27</sup> However, the ISG criteria for BD do not include intestinal symptoms.

## Diagnostic Tests

The diagnosis of BD is based on clinical findings, as there is no pathognomonic laboratory test. Patients with active BD may have elevated levels of serum markers of inflammation, such as C-reactive protein (CRP) and erythrocyte sedimentation rate; however, these findings are not specific and may also be observed in patients with IBD or other forms of vasculitis. Patients with active BD often have elevated levels of serum immunoglobulin (Ig)D.<sup>1</sup> Serum IgA and complement levels may also be elevated in BD patients, in whom antinuclear antibodies and rheumatoid factor autoantibodies are typically absent.<sup>3</sup>

Positive results from a pathergy test have limited reproducibility and vary greatly, depending on geographic location (60% in Middle Eastern populations, 15% in Korean populations, and 5% in North American populations).<sup>1</sup> The pathergy test is a hypersensitivity reaction to a sterile needle prick; a 20–22-gauge sterile needle is inserted 5 mm into the skin in a perpendicular or oblique manner at 3 different places on each forearm.<sup>15</sup> The presence of a erythematous papule, pustule, or ulcer larger than 2 mm after 48 hours indicates a positive pathergy test result.<sup>15</sup> However, positive test results can also be seen in patients with Sweet syndrome, pyoderma gangrenosum, and IBD (10% of CD patients and 7% of UC patients) without coexisting BD.<sup>1,6,28</sup> Positive pathergy test results are not associated

**Table 3.** International Study Group Diagnostic Criteria for Behçet Disease

Criterion	Description
Recurrent oral ulcerations	Minor or major aphthous ulcerations or herpetiform ulcerations observed by a physician or patient that have recurred at least 3 times in a 12-month period
Plus 2 of the following criteria in the absence of other clinical explanations:	
Recurrent genital ulcerations	Aphthous ulcerations or scarring observed by a physician or patient
Eye lesions	Anterior or posterior uveitis or vitreous cells seen on slit-lamp examination; retinal vasculitis observed by an ophthalmologist
Skin lesions	Erythema nodosum observed by a physician or patient; pseudofolliculitis; papulopustular lesions; acneiform nodules observed by a physician in postadolescent patients who are not taking corticosteroids
Positive results from a pathergy test	Oblique insertion of a 20–22-gauge needle 5 mm into the skin, causing a papule 2 mm or larger. The test is generally performed on the forearm, and results are read by a physician after 24–48 hours.

Adapted from International Study Group for Behçet's Disease.<sup>26</sup>

with disease activity or specific disease manifestations, but results are more strongly positive in males.<sup>15</sup>

## Radiographic Imaging

A barium swallow study may be performed in patients with upper intestinal symptoms; however, superficial ulcers may be missed. Pyloric stenosis without duodenal deformity is a characteristic finding in BD with upper GI involvement.<sup>3</sup> Computed tomography (CT) scan/enterography and magnetic resonance (MR) enterography/enteroclysis are useful for diagnosing small bowel disease in both intestinal BD and CD, but these imaging modalities may not be routinely available.<sup>6</sup> A double-contrast barium enema may be useful for identifying colonic lesions in BD and determining the extent of these lesions. Colonic haustra are typically preserved in patients with BD, unlike in patients with UC.<sup>3</sup> Kim and colleagues reviewed double-contrast barium enema findings in 20 patients with intestinal BD and found cecal deformity

with incompetence of the ileocecal valve in 95% of cases and a single ulcer averaging 2.7 cm in diameter in 75% of patients.<sup>29</sup> Intestinal BD ulcers are mainly located in the ileocecal region, are ovoid or geographic in shape, and may be described as a collar button. Diffuse colonic involvement is rare in intestinal BD, unlike in UC. CT and MR scans are useful for demonstrating colonic wall thickening and evaluating extraluminal complications, such as abscesses or perforations.<sup>6</sup>

## Endoscopic Findings

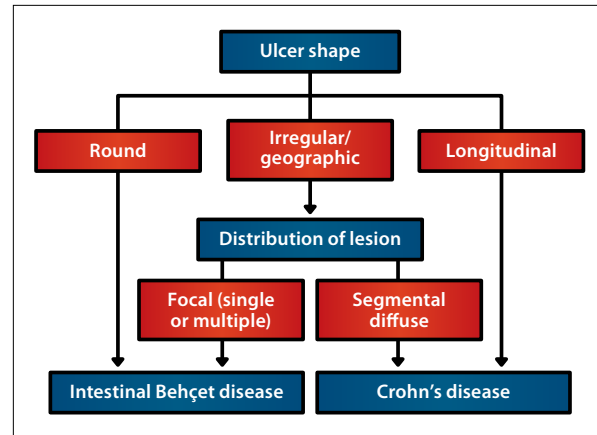
Ulcers seen on colonoscopy are typically irregular, round or oval, punched-out, large (>1 cm), single to few in number, deep, and with discrete margins in a focal distribution.<sup>3</sup> Ninety-six percent of surgery-naïve patients with intestinal BD have lesions in the ileocecal region, with 67% of patients having only a single ulcer.<sup>30</sup> Colonic ulcers have also been described as volcano-type lesions because they are deeply penetrating and have nodular margins caused by fibrosis.<sup>31</sup> These ulcers are less responsive to medical therapy and frequently require surgical resection.<sup>19,31</sup> Fistula formation, hemorrhage, or perforation occurs in approximately 50% of cases involving the intestine.<sup>32</sup>

Diffuse colonic involvement is rare, but it occurs in approximately 15% of patients who have GI involvement.<sup>33</sup> Rectal and anal involvement is extremely rare, with only a few reported cases of isolated proctitis.<sup>22</sup> Although patients with intestinal BD may not have macroscopic ileal lesions on colonoscopy, up to 61% have abnormal ileal histology.<sup>34</sup> Wireless capsule endoscopy may be useful for identifying ulcers in the small bowel.<sup>35</sup> Double-balloon enteroscopy may be necessary in order to obtain small bowel tissue to establish a definitive diagnosis.<sup>36</sup>

## Differential Diagnosis

GI manifestations of BD must be differentiated from those associated with infectious enterocolitis, intestinal tuberculosis (TB), IBD, other causes of colitis, appendicitis, and diverticulitis.

Intestinal BD often mimics IBD, particularly CD. Both diseases occur in younger patients and have nonspecific GI symptoms, similar extraintestinal manifestations and complications, and disease courses that wax and wane over time.<sup>6</sup> CD is a chronic, relapsing, transmural, inflammatory disease that can affect the entire GI tract (ie, from the mouth to the anus) and typically presents with nonbloody diarrhea and abdominal pain. In CD, classic colonoscopic findings include longitudinal ulcers with a cobblestone appearance and discontinuous involvement of various portions of the GI tract.<sup>30</sup> The development of complications such as strictures, fistulae, and abscesses is common in CD.<sup>37</sup>



**Figure 1.** Proposed classification scheme for differentiating between intestinal Behçet disease and Crohn's disease.

Adapted from Lee SK, Kim BK, Kim TI, Kim WH.<sup>38</sup>

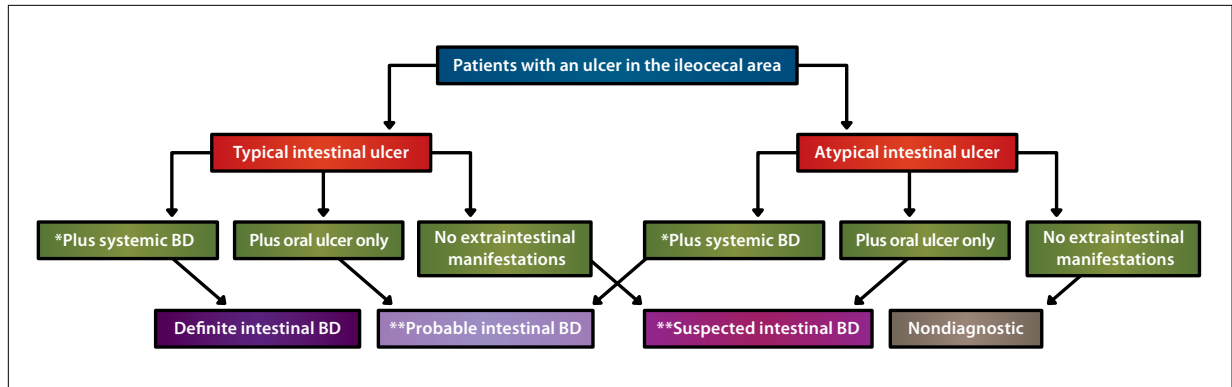
Intestinal TB may be difficult to distinguish from intestinal BD and CD both clinically and endoscopically. Patients with intestinal TB often present with right lower quadrant abdominal pain, fever with night sweats, anemia, and weight loss.<sup>3</sup> A T-SPOT TB blood test may be a useful tool for diagnosing intestinal TB.<sup>37</sup> Differentiating intestinal BD from intestinal TB is particularly important in geographic regions where both diseases are common, as treatments for the 2 diseases are completely different.<sup>6</sup> Biopsies obtained during colonoscopy for culture and polymerase chain reaction testing for *Mycobacterium tuberculosis* can help to determine the appropriate diagnosis.<sup>6</sup>

Because patients with intestinal BD are often on CS therapy to control their symptoms, intestinal ulcers due to BD must be differentiated from CS-induced or nonsteroidal anti-inflammatory drug (NSAID)-induced ulcers. Ulcers in intestinal BD tend to be deeper, larger, and more numerous than NSAID-induced ulcers.<sup>3</sup>

Intestinal amebiasis is common in Middle Eastern populations, and a fresh stool sample should be obtained to look for ova and parasites in these patients. Amebiasis is typically localized to the ileocecal region, with 90% of chronic amebiasis involving the cecum.<sup>3</sup> Ulcers in BD are deeper and do not have lateral extension, compared to those in patients with intestinal amebiasis.

## Differences in Clinical Manifestations Between Intestinal Behçet Disease and Inflammatory Bowel Disease

As mentioned above, common presenting symptoms of both intestinal BD and IBD include diarrhea, abdominal pain, and GIB. The ileocecal region is the most commonly affected part of the GI tract in intestinal BD; involve-



**Figure 2.** Algorithm for the diagnosis of intestinal Behçet disease (BD).

\*Subtypes of systemic BD were classified according to the diagnostic criteria of the Research Committee of Japan. \*\*Close follow-up surveillance is necessary.

Adapted from Cheon JH, Kim ES, Shin SJ, et al.<sup>40</sup>

ment in this area may be mistaken for CD. Ulcers that are irregular, round or oval, punched-out, large (>1 cm), deep, and with discrete margins in a focal distribution are more common in intestinal BD; in contrast, segmental, diffuse, longitudinal lesions may suggest CD.<sup>3,19</sup> Lee and coworkers were able to differentiate between intestinal BD and CD in more than 90% of cases based on the shape and distribution patterns of ulcers on colonoscopy (Figure 1).<sup>38</sup> Intestinal BD can also present as longitudinal ulcers with or without granulomas.<sup>32,39</sup>

In addition, Lee and associates showed that a round ulcer shape, focal distribution, presence of less than 6 ulcers, absence of aphthous lesions, and lack of cobblestone appearance were independent colonoscopic findings more commonly found in intestinal BD than in CD.<sup>38</sup> In 2009, Cheon and colleagues proposed an algorithm for the diagnosis of intestinal BD based on clinical manifestations and the type of ileocolonic ulcers (Figure 2).<sup>40</sup> After combining the definite, probable, and suspected groups, the sensitivity and specificity of this algorithm for diagnosing intestinal BD were 99% and 83%, respectively.<sup>40</sup>

Transmural enteritis or colitis can occur in intestinal BD or CD, but the presence of granulomas on biopsy suggests CD, whereas the finding of vasculitis suggests intestinal BD.<sup>19</sup> Focal colitis has been documented in colorectal biopsies of patients with intestinal BD in whom there was no evidence of disease via radiographic or endoscopic evaluation.<sup>19</sup>

Perianal disease is very rare in intestinal BD and supports the diagnosis of CD.<sup>20</sup> Fistula formation and intestinal perforation may occur in both intestinal BD and CD; however, these symptoms usually occur earlier in the clinical course of intestinal BD.<sup>3</sup> Severe GIB is more common in patients with intestinal BD than in patients with CD.<sup>41</sup> Nevertheless, the distinction may

be extremely difficult to make, leading to the patient receiving both diagnoses.

### Differences in Extraintestinal Manifestations Between Behçet Disease and Inflammatory Bowel Disease

The extraintestinal manifestations of BD may be confused with those of IBD, specifically uveitis, arthritis, oral ulcers, pyoderma gangrenosum, vaso-occlusive disease, and thrombotic events. Iritis and episcleritis are more indicative of IBD, while genital lesions, papulopustular lesions, and neurologic involvement are more common in BD. Vascular complications can occur in up to one third of BD patients.<sup>42</sup> Patients with IBD have a 3–4-fold increased risk of venous thrombosis, and IBD is an independent risk factor for thrombosis. However, the etiology of this association is not clear.<sup>43,44</sup> In the absence of extraintestinal manifestations, it may be impossible to distinguish intestinal BD from CD.

### Role of Serum Antibodies

Various autoantibodies have been described in IBD, specifically perinuclear antineutrophil cytoplasmic autoantibody (pANCA) in UC and anti-*Saccharomyces cerevisiae* antibody (ASCA) in CD. ASCA is directed against the oligomannosidic epitope of the yeast *S. cerevisiae* and is positive in 40–70% of patients with CD, 10–15% of patients with UC, and 0–5% of healthy control subjects.<sup>20</sup> ASCA positivity is associated with a greater risk of disease recurrence and multiple bowel resections in CD. ASCA positivity may be found in up to 44% of patients with intestinal BD but only 3–4% of patients with nonintestinal

BD and 9% of healthy control subjects.<sup>20,45</sup> ASCA positivity is associated with an increased number and frequency of operations in patients with intestinal BD.<sup>20</sup>

pANCA is positive in 60–80% of UC patients and 10–30% of CD patients. In a Turkish study involving 18 patients with known BD, none were pANCA-positive.<sup>46</sup>

Antiendothelial cell antibody (AECA) has been detected in patients with BD.<sup>47</sup> Anti- $\alpha$ -enolase antibody is a target protein of serum AECA in BD patients and may be associated with disease activity and severity.<sup>47</sup>

## Treatment

Treatment depends on the patient's clinical manifestations, with priority given to ocular, intestinal, and central nervous system symptoms as well as large-vessel vasculitis, as these manifestations tend to have the most severe complications. Treatment of ocular lesions is critical for reducing the severity and frequency of ocular attacks, which can cause blindness; emergent ophthalmologic evaluation is imperative to help prevent blindness.<sup>48</sup> Infliximab (Remicade, Janssen Biotech) is often first-line therapy for sight-threatening bilateral posterior uveitis.<sup>49</sup> In patients with severe uveitis and intestinal BD, colectomy has been shown to improve uveitis in a few cases.<sup>50</sup> In another case, a patient with refractory intestinal BD and pyoderma gangrenosum underwent a total colectomy, resulting in rapid improvement of the pyoderma gangrenosum.<sup>51</sup>

### Medical Treatment

The medical treatments used for intestinal BD are often identical to those used for IBD. Sulfasalazine (1–4 g/day) or mesalamine (5-aminosalicylic acid [5-ASA]; 2–4 g/day) and CSs are the main therapies used to treat intestinal BD.<sup>6</sup> However, 5-ASAs should only be used to treat intestinal BD if clinical and endoscopic activity are mild.<sup>6</sup> CSs are often first-line therapy during the acute phase of intestinal BD or in patients with severe systemic symptoms, recurrent GIB, or moderate/severe disease activity.<sup>6</sup> The dosage of oral CSs depends on the severity of the lesions and ranges from 20 mg/day to 100 mg/day of prednisolone.<sup>1</sup> Intravenous pulse doses of methylprednisolone (1 g/day for 3 days) may be used if necessary.<sup>6</sup> Approximately 46% of patients have complete remission 1 month after starting CS therapy, but 43% only have partial remission, and 11% have no response.<sup>52</sup> At 3 months, prolonged response to CS therapy drops to 41%; in addition, 46% of patients are CS-dependent, and 7% require surgical intervention.<sup>52</sup>

Although CSs are the main treatment for intestinal BD, many patients become CS-resistant or CS-dependent. Azathioprine (2.0–2.5 mg/kg/day) has been used in intestinal BD to help reduce the dose of CSs and, in some cases,

to completely stop CS therapy.<sup>53</sup> Confirmed endoscopic remission was seen in 75% of azathioprine-treated patients, with a 32-month median duration of remission.<sup>53</sup> Azathioprine appears to be more effective in women ( $P=.014$ ) for unknown reasons.<sup>53</sup> A Korean study of patients on azathioprine maintenance therapy after an initial operation reported decreased reoperation rates: 18% at 2 years and 22% at 5 years ( $P=.035$ ).<sup>54</sup>

Patients with intestinal BD have also been successfully treated with thalidomide (2 mg/kg/day), with this drug achieving symptom control and alleviating CS dependency.<sup>55</sup> Similar to its use in CD, etanercept (Enbrel, Immunex) has not been shown to be beneficial in patients with intestinal BD.<sup>56</sup>

TNF- $\alpha$  is an important agent in the inflammatory process observed in BD; hence, infliximab, a chimeric monoclonal antibody to TNF- $\alpha$ , is beneficial in patients who are unresponsive to conventional therapies. Treatment of intestinal BD usually requires a combination of medical and surgical therapies, much like the treatment of IBD. Infliximab has been shown to be effective for induction and maintenance treatment in patients with severe mucocutaneous, intestinal, and ocular manifestations of BD.<sup>57</sup>

The standard dosage of infliximab for treatment of intestinal BD has not been established; therefore, the treatment dose and protocol for CD are typically used.<sup>57</sup> Maintenance infliximab treatment has been shown to be more beneficial than short-term treatment for maintaining remission in patients with intestinal BD.<sup>58</sup> Patients on anti-TNF- $\alpha$  agents must be monitored closely for infections, malignancies, demyelinating diseases, and congestive heart failure. Table 4 lists groups of patients with BD who may benefit from anti-TNF- $\alpha$  therapy.<sup>49</sup>

The first case of BD treated with infliximab was reported in 2001.<sup>59</sup> Infliximab led to rapid and complete resolution of the patient's intestinal and extraintestinal symptoms, and this benefit was maintained even after CS discontinuation.<sup>59</sup> Ju and coworkers reported a case of severe, life-threatening GIB caused by an ileal ulcer in a patient with intestinal BD who was successfully treated with infliximab.<sup>60</sup> Iwata and associates reported long-term alleviation of intestinal BD symptoms in patients treated with a combination of methotrexate and infliximab without severe adverse events.<sup>58</sup> The effects of this treatment persisted for up to 58 months, and patients were able to taper CS doses from an average of 22 mg/day to 1.8 mg/day by 24 months.<sup>58</sup>

Intestinal BD has also been successfully treated with adalimumab (Humira, Abbott), a fully humanized IgG1 monoclonal antibody that binds to TNF- $\alpha$ .<sup>61</sup> Ariyachai-panich and colleagues described a patient with CS-dependent, immunosuppressive-refractory intestinal BD who maintained remission on adalimumab monotherapy after

**Table 4.** Patients with Behçet Disease Who May Benefit From Anti-Tumor Necrosis Factor (TNF)- $\alpha$  Therapy

- Patients who have a definite diagnosis of Behçet disease
- Patients who have active disease, including objective signs of inflammation
- Patients who have failed treatment with drugs that have a documented efficacy for controlling Behçet disease manifestations; these patients may also have taken low-dose corticosteroids (equivalent to a prednisolone dose  $\leq 7.5$  mg/day)
- Patients who have contraindications or intolerance to conventional therapeutic regimens
- Patients who do not have contraindications to anti-TNF- $\alpha$  treatment
- Patients with intestinal inflammation, chronic arthritis, and/or mucocutaneous manifestations that significantly impair quality of life

The first 3 groups of patients outlined above typically have severe disease and are likely to benefit from anti-TNF- $\alpha$  therapy. Severe disease is defined as 2 or more relapses of posterior uveitis or panuveitis per year, low visual acuity due to chronic cystoid macular edema, and active central nervous system parenchymal disease.

Adapted from Sfikakis PP, Markomichelakis N, Alpsyoy E, et al.<sup>49</sup>

remission was induced with combination infliximab and azathioprine therapy.<sup>62</sup> More recently, adalimumab has been successfully used as a first-line anti-TNF- $\alpha$  agent in patients with steroid-dependent intestinal BD to induce and maintain complete remission.<sup>63</sup>

In one study, only 38% of patients achieved complete remission of intestinal lesions after 8 weeks of medical therapy.<sup>54</sup> Intestinal manifestations of BD appear to have a more sustained response to anti-TNF- $\alpha$  therapy than other manifestations of BD.<sup>64</sup> Despite several case series showing the efficacy of anti-TNF- $\alpha$  agents in intestinal BD, a prospective, randomized, placebo-controlled trial is needed to validate these findings.

### **Surgical Management**

Patients who present with severe GIB and abdominal pain may require surgery for persistent bleeding or perforation. Other indications for surgery include fistulae, obstructions, abdominal masses, and failure to respond to medical therapy.<sup>65</sup> Creation of a stoma is often preferred over primary anastomosis, due to the high rates of intestinal leakage, perforation, and fistula formation at the anastomotic site.<sup>3</sup> The first choice in terms of surgical procedure and length of bowel resection is controversial.<sup>6</sup> Disease recurrence is seen in 40–80% of patients and is often found at or near the anastomotic

site, as with CD.<sup>5,65</sup> Up to 80% of patients with disease recurrence require a repeat operation due to failure of medical therapy, perforation, or fistula formation.<sup>1,3</sup> Follow-up radiographic and endoscopic imaging should begin within 2 years after surgery, with initiation of early medical treatment if disease activity is present.<sup>3</sup>

Moon and coworkers evaluated 129 BD patients over 20 years to determine risk factors associated with free bowel perforation; independent factors were found to be age 25 years or younger at the time of diagnosis ( $P=.006$ ), prior history of laparotomy ( $P=.0001$ ), and volcano-shaped ulcers seen on colonoscopy ( $P=.025$ ).<sup>5</sup> Disease recurrence is frequent, even after surgical resection, and may be associated with more severe symptoms.<sup>66</sup> Extensive ileal disease and ocular lesions are markers of increased disease severity and progression to surgical resection.<sup>66</sup> Independent predictive factors for recurrence include volcano-shaped ulcers, CRP levels greater than 4.4 mg/dL, and the presence of intestinal perforations on pathology; independent predictive factors for reoperation include a history of postoperative steroid therapy, CRP levels greater than 4.4 mg/dL, and volcano-shaped ulcers.<sup>65</sup>

### **Prognosis**

The overall prognosis in intestinal BD is more guarded than in CD. Remission rates with medical therapy are similar to those achieved in CD patients, but recurrence rates are higher and patients require surgical intervention more frequently in intestinal BD.<sup>6</sup> Poor prognostic factors include volcano-shaped ulcers, higher CRP levels, history of postoperative CS therapy, presence of intestinal perforation on pathology, extensive ileal disease, presence of ocular disease, and positive ASCA status.<sup>20,65</sup>

### **Summary**

Although BD is very rare in the United States, physicians will encounter these challenging patients more frequently in the future due to increased immigration rates of Asian and Mediterranean populations. Diagnosis of BD is based on clinical findings, as there is no pathognomonic laboratory test. Although treatment of intestinal BD is similar to that of IBD, the prognosis is worse for intestinal BD.

### **References**

1. Sakane T, Takeno M, Suzuki N, Inaba G. Behçet's disease. *N Engl J Med*. 1999;341:1284-1291.
2. Behçet H. Rezidivierende Aphthose, durch ein Virus verursachte Geschwüre am Auge und an den Genitalien. *Dermatol Wochenschr*. 1937;105:1152-1157.
3. Bayraktar Y, Ozaslan E, Van Thiel DH. Gastrointestinal manifestations of Behçet's disease. *J Clin Gastroenterol*. 2000;30:144-154.



4. Cheon JH, Han DS, Park JY, et al; Korean IBD Study Group. Development, validation, and responsiveness of a novel disease activity index for intestinal Behçet's disease. *Inflamm Bowel Dis*. 2011;17:605-613.
5. Moon CM, Cheon JH, Shin JK, et al. Prediction of free bowel perforation in patients with intestinal Behçet's disease using clinical and colonoscopic findings. *Dig Dis Sci*. 2010;55:2904-2911.
6. Cheon JH, Celik AF, Kim WH. Behçet's disease: gastrointestinal involvement. In: Yazici Y, Yazici H, eds. *Behçet's Syndrome*. 1st ed. New York, NY: Springer; 2010:165-188.
7. Direskeneli H. Behçet's disease: infectious aetiology, new autoantigens, and HLA-B51. *Ann Rheum Dis*. 2001;60:996-1002.
8. Remmers EF, Cosan F, Kirino Y, et al. Genome-wide association study identifies variants in the MHC class I, IL10, and IL23R-IL12RB2 regions associated with Behçet's disease. *Nat Genet*. 2010;42:698-702.
9. Franke A, McGovern DP, Barrett JC, et al. Genome-wide meta-analysis increases to 71 the number of confirmed Crohn's disease susceptibility loci. *Nat Genet*. 2010;42:1118-1125.
10. Meguro A, Inoko H, Ota M, et al. Genetics of Behçet disease inside and outside the MHC. *Ann Rheum Dis*. 2010;69:747-754.
11. Smith EL, Yazici Y. Pathogenesis of Behçet's disease. UpToDate [website]. Updated February 10, 2011. [http://www.uptodate.com/contents/pathogenesis-of-behçets-disease?source=search\\_result](http://www.uptodate.com/contents/pathogenesis-of-behçets-disease?source=search_result). Accessed May 4, 2011.
12. Baskan EB, Yilmaz E, Saricaoglu H, et al. Detection of parvovirus B19 DNA in the lesional skin of patients with Behçet's disease. *Clin Exp Dermatol*. 2007;32:186-190.
13. Kobayashi T, Sudo Y, Okamura S, et al. Monozygotic twins concordant for intestinal Behçet's disease. *J Gastroenterol*. 2005;40:421-425.
14. Soy M, Erken E, Konca K, Ozbek S. Smoking and Behçet's disease. *Clin Rheumatol*. 2000;19:508-509.
15. Barnes CG. History and diagnosis. In: Yazici Y, Yazici H, eds. *Behçet's Syndrome*. 1st ed. New York, NY: Springer; 2010:7-34.
16. Turan B, Gallati H, Erdi H, Gürler A, Michel BA, Villiger PM. Systemic levels of the T cell regulatory cytokines IL-10 and IL-12 in Behçet's disease; soluble TNFR-75 as a biological marker of disease activity. *J Rheumatol*. 1997;24:128-132.
17. Hatemi G, Fresko I, Tascilar K, Yazici H. Increased enthesopathy among Behçet's syndrome patients with acne and arthritis: an ultrasonography study. *Arthritis Rheum*. 2008;58:1539-1545.
18. Alpsoy E, Donmez L, Onder M, et al. Clinical features and natural course of Behçet's disease in 661 cases: a multicentre study. *Br J Dermatol*. 2007;157:901-906.
19. Sayek I, Aran O, Uzunalmoglu B, Hersek E. Intestinal Behçet's disease: surgical experience in seven cases. *Hepatogastroenterology*. 1991;38:81-83.
20. Choi CH, Kim TI, Kim BC, et al. Anti-*Saccharomyces cerevisiae* antibody in intestinal Behçet's disease patients: relation to clinical course. *Dis Colon Rectum*. 2006;49:1849-1859.
21. Kyle SM, Yeong ML, Isbister WH, Clark SP. Behçet's colitis: a differential diagnosis in inflammations of the large intestine. *Aust N Z J Surg*. 1991;61:547-550.
22. Hamza M. Proctitis in Behçet disease. Study of 6 cases [in French]. *Rev Rhum Ed Fr*. 1993;60:925-927.
23. Lebowitz O, Forde KA, Berdon WE, Morrison S, Challop R. Ulcerative esophagitis and colitis in a pediatric patient with Behçet's syndrome. Response to steroid therapy. *Am J Gastroenterol*. 1977;68:550-555.
24. Ben Ghorbel I, Ennaifer R, Lamloum M, Khanfir M, Miled M, Houman MH. Budd-Chiari syndrome associated with Behçet's disease. *Gastroenterol Clin Biol*. 2008;32:316-320.
25. Lakhnopal S, Tani K, Lie JT, Katoh K, Ishigatsubo Y, Ohokubo T. Pathologic features of Behçet's syndrome: a review of Japanese autopsy registry data. *Hum Pathol*. 1985;16:790-795.
26. International Study Group for Behçet's Disease. Criteria for diagnosis of Behçet's disease. *Lancet*. 1990;335:1078-1080.
27. Tunç R, Uluhan A, Melikoğlu M, Ozyazgan Y, Ozdoğan H, Yazici H. A reassessment of the International Study Group criteria for the diagnosis (classification) of Behçet's syndrome. *Clin Exp Rheumatol*. 2001;19(5 suppl 24):S45-S47.
28. Hatemi I, Hatemi G, Celik AF, et al. Frequency of pathergy phenomenon and other features of Behçet's syndrome among patients with inflammatory bowel disease. *Clin Exp Rheumatol*. 2008;26(4 suppl 50):S91-S95.
29. Kim JH, Choi BI, Han JK, Choo SW, Han MC. Colitis in Behçet's disease: characteristics on double-contrast barium enema examination in 20 patients. *Abdom Imaging*. 1994;19:132-136.
30. Lee CR, Kim WH, Cho YS, et al. Colonoscopic findings in intestinal Behçet's disease. *Inflamm Bowel Dis*. 2001;7:243-249.
31. Kim JS, Lim SH, Choi JJ, et al. Prediction of the clinical course of Behçet's colitis according to macroscopic classification by colonoscopy. *Endoscopy*. 2000;32:635-640.
32. Kim ES, Chung WC, Lee KM, et al. A case of intestinal Behçet's disease similar to Crohn's colitis. *J Korean Med Sci*. 2007;22:918-922.
33. Masugi J, Matsui T, Fujimori T, Maeda S. A case of Behçet's disease with multiple longitudinal ulcers all over the colon. *Am J Gastroenterol*. 1994;89:778-780.
34. Köklü S, Yüksel O, Onur I, et al. Ileocolonic involvement in Behçet's disease: endoscopic and histologic evaluation. *Digestion*. 2010;81:214-217.
35. Hamdulay SS, Cheent K, Ghosh C, Stocks J, Ghosh S, Haskard DO. Wireless capsule endoscopy in the investigation of intestinal Behçet's syndrome. *Rheumatology (Oxford)*. 2008;47:1231-1234.
36. Chang DK, Kim JJ, Choi H, et al. Double balloon endoscopy in small intestinal Crohn's disease and other inflammatory diseases such as cryptogenic multifocal ulcerous stenosing enteritis (CMUSE). *Gastrointest Endosc*. 2007;66(3 suppl):S96-S98.
37. Lee JN, Ryu DY, Park SH, et al. The usefulness of in vitro interferon-gamma assay for differential diagnosis between intestinal tuberculosis and Crohn's disease [in Korean]. *Korean J Gastroenterol*. 2010;55:376-383.
38. Lee SK, Kim BK, Kim TI, Kim WH. Differential diagnosis of intestinal Behçet's disease and Crohn's disease by colonoscopic findings. *Endoscopy*. 2009;41:9-16.
39. Naganuma M, Iwao Y, Kashiwagi K, Funakoshi S, Ishii H, Hibi T. A case of Behçet's disease accompanied by colitis with longitudinal ulcers and granuloma. *J Gastroenterol Hepatol*. 2002;17:105-108.
40. Cheon JH, Kim ES, Shin SJ, et al. Development and validation of novel diagnostic criteria for intestinal Behçet's disease in Korean patients with ileocolonic ulcers. *Am J Gastroenterol*. 2009;104:2492-2499.
41. Goldstein SJ, Crooks DJ. Colitis in Behçet's syndrome. Two new cases. *Radiology*. 1978;128:321-323.
42. Koç Y, Güllü I, Akpek G, et al. Vascular involvement in Behçet's disease. *J Rheumatol*. 1992;19:402-410.
43. Bernstein CN, Blanchard JF, Houston DS, Wajda A. The incidence of deep venous thrombosis and pulmonary embolism among patients with inflammatory bowel disease: a population-based cohort study. *Thromb Haemost*. 2001;85:430-434.
44. Papa A, Scaldaferrri F, Danese S, et al. Vascular involvement in inflammatory bowel disease: pathogenesis and clinical aspects. *Dig Dis*. 2008;26:149-155.
45. Fresko I, Ugurlu S, Ozbakir F, et al. Anti-*Saccharomyces cerevisiae* antibodies (ASCA) in Behçet's syndrome. *Clin Exp Rheumatol*. 2005;23(4 suppl 38):S67-S70.
46. Filik I, Biyikoğlu I. Differentiation of Behçet's disease from inflammatory bowel diseases: anti-*Saccharomyces cerevisiae* antibody and anti-neutrophilic cytoplasmic antibody. *World J Gastroenterol*. 2008;14:7271.
47. Shin SJ, Kim BC, Kim TI, Lee SK, Lee KH, Kim WH. Anti-alpha-enolase antibody as a serologic marker and its correlation with disease severity in intestinal Behçet's disease. *Dig Dis Sci*. 2011;56:812-818.
48. Ozyazgan Y, Bodaghi B. Eye disease in Behçet's syndrome. In: Yazici Y, Yazici H, eds. *Behçet's Syndrome*. 1st ed. New York, NY: Springer; 2010:73-94.
49. Sfikakis PP, Markomichelakis N, Alpsoy E, et al. Anti-TNF therapy in the management of Behçet's disease—review and basis for recommendations. *Rheumatology (Oxford)*. 2007;46:736-741.
50. Mintz R, Feller ER, Bahr RL, Shah SA. Ocular manifestations of inflammatory bowel disease. *Inflamm Bowel Dis*. 2004;10:135-139.
51. Nakamura T, Yagi H, Kurachi K, Suzuki S, Konno H. Intestinal Behçet's disease with pyoderma gangrenosum: a case report. *World J Gastroenterol*. 2006;12:979-981.
52. Park JJ, Cheon JH, Moon CM, et al. Long-term clinical outcomes after the first course of corticosteroid therapy in patients with moderate to severe intestinal Behçet's disease. Presented at Digestive Disease Week; May 1-5, 2010; New Orleans, Louisiana. Abstract W1321.
53. Sogawa M, Hosomi S, Takatsuka M, et al. Evaluation of the usefulness of azathioprine therapy in intestinal Behçet's disease. Presented at Digestive Disease Week; May 1-5, 2010; New Orleans, Louisiana. Abstract W1332.
54. Choi JJ, Kim JS, Cha SD, et al. Long-term clinical course and prognostic factors in intestinal Behçet's disease. *Dis Colon Rectum*. 2000;43:692-700.
55. Yasui K, Uchida N, Akazawa Y, et al. Thalidomide for treatment of intestinal involvement of juvenile-onset Behçet disease. *Inflamm Bowel Dis*. 2008;14:396-400.
56. Estrach C, Mpfu S, Moorts RJ. Behçet's syndrome: response to infliximab after failure of entanercept. *Rheumatology (Oxford)*. 2002;41:1213-1214.

57. Lee JH, Kim TN, Choi ST, et al. Remission of intestinal Behçet's disease treated with anti-tumor necrosis factor  $\alpha$  monoclonal antibody (infliximab). *Korean J Intern Med.* 2007;22:24-27.
58. Iwata S, Saito K, Yamaoka K, et al. Efficacy of combination therapy of anti-TNF alpha antibody infliximab and methotrexate in refractory entero-Behçet's disease. *Mod Rheumatol.* 2011;21:184-191.
59. Hassard PV, Binder SW, Nelson V, Vasiliauskas EA. Anti-tumor necrosis factor monoclonal antibody therapy for gastrointestinal Behçet's disease: a case report. *Gastroenterology.* 2001;120:995-999.
60. Ju JH, Kwok SK, Seo SH, et al. Successful treatment of life-threatening intestinal ulcer in Behçet's disease with infliximab: rapid healing of Behçet's ulcer with infliximab. *Clin Rheumatol.* 2007;26:1383-1385.
61. Bawazeer A, Raffa LH, Nizamuddin SH. Clinical experience with adalimumab in the treatment of ocular Behçet disease. *Ocul Immunol Inflamm.* 2010;18:226-232.
62. Ariyachaipanich A, Berkelhammer C, Nicola H. Intestinal Behçet's disease: maintenance of remission with adalimumab monotherapy. *Inflamm Bowel Dis.* 2009;15:1769-1771.
63. De Cassan C, De Vroey B, Dussault C, Hachulla E, Buche S, Colombel JF. Successful treatment with adalimumab in a familial case of gastrointestinal Behçet's disease. *J Crohns Colitis.* 2011;5:364-368.
64. Hatemi G, Hamuryudan V, Yurdakul S, et al. Efficacy and safety of TNF-alpha antagonists in the management of Behçet's syndrome: a systemic review. Presented at the ACR/ARHP Annual Scientific Meeting; October 16-21, 2009; Philadelphia, Pennsylvania. Abstract 1845.
65. Jung YS, Yoon JY, Lee JH, et al. Prognostic factors and long-term clinical outcomes for surgical patients with intestinal Behçet's disease. *Inflamm Bowel Dis.* 2011;17:1594-1602.
66. Naganuma M, Iwao Y, Inoue N, et al. Analysis of clinical course and long-term prognosis of surgical and nonsurgical patients with intestinal Behçet's disease. *Am J Gastroenterol.* 2000;95:2848-2851.