

# Spontaneous Colonic Perforation in a Patient with Collagenous Colitis

Michael Bennett, MD<sup>1</sup>  
 Hillary Tompkins, MD<sup>1</sup>  
 Bridget Seymour, MD<sup>2</sup>  
 Michael J. O'Brien, MD<sup>3</sup>  
 Francis A. Farraye, MD, MSc<sup>1</sup>

<sup>1</sup>Section of Gastroenterology, Boston Medical Center, Boston, Massachusetts; <sup>2</sup>Merrimack Valley Gastroenterology, Haverhill, Massachusetts; <sup>3</sup>Department of Pathology, Boston Medical Center, Boston, Massachusetts

## Case Report

An otherwise healthy woman, age 67 years, presented in 2009 with the complaint of loose, nonbloody stools of 2 months' duration. The patient reported having up to 6 bowel movements daily that sometimes occurred at night and were accompanied by lower abdominal cramping and urgency. The symptoms were not associated with food intake. The patient took aspirin but no other nonsteroidal anti-inflammatory drugs (NSAIDs). The symptoms were partially relieved by loperamide. Physical examination findings were unremarkable. Infectious causes as well as celiac disease were ruled out. A colonoscopy was planned for further evaluation.

Prior to the colonoscopy, the patient was admitted to the hospital with abdominal pain, diarrhea, and rigors. A computed tomography scan of the abdomen revealed bowel wall thickening at the splenic flexure with pockets of extraluminal air and pneumatosis. There was no evidence of diverticular disease. The patient underwent partial colectomy and transverse colostomy with a mucus fistula. Surgical pathology revealed colonic mucosa with a thickened subepithelial collagen plate consistent with collagenous colitis (Figures 1 and 2).

Postoperatively, the patient continued to have frequent loose stools from her ostomy. Endoscopic findings from a colonoscopy through the stoma in January 2010 were normal, but pathology again demonstrated collagenous colitis. In March 2010, the patient underwent takedown of her stoma and colo-colonic anastomosis. The patient continued to have frequent loose stools. She received 2 courses of budesonide in 2010 and was later treated with a short course of mesalamine. Her diarrhea resolved, and she now has formed daily bowel movements and no longer requires pharmacotherapy.

Address correspondence to:  
 Dr. Francis A. Farraye, Section of Gastroenterology, Boston Medical Center,  
 85 East Concord Street, Boston, MA 02052; Tel: 617-638-8339;  
 E-mail: francis.farraye@bmc.org

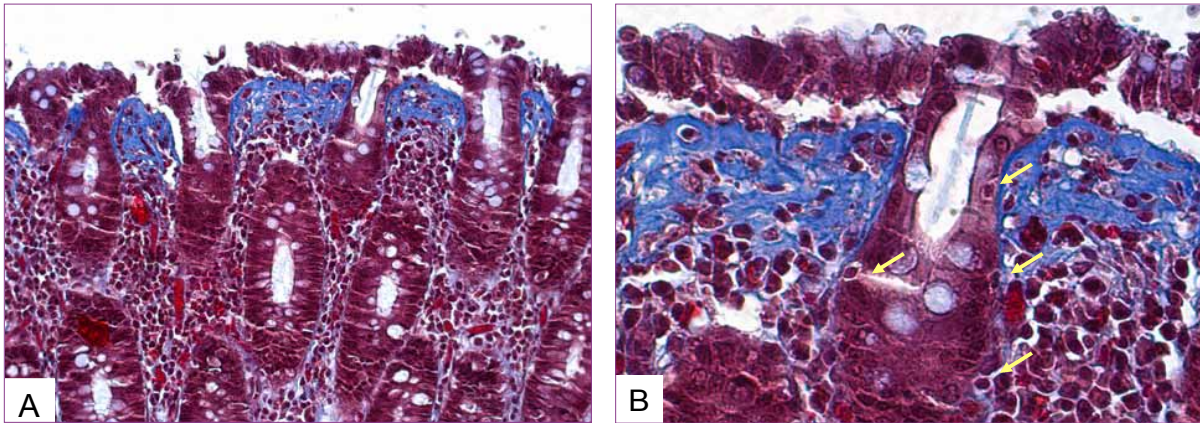
## Discussion

Collagenous colitis is a relatively uncommon but increasingly diagnosed form of microscopic colitis. First described in 2 independent reports in 1976,<sup>1,2</sup> it is characterized by a clinical syndrome of chronic or recurrent watery diarrhea and a grossly normal appearance of colonic mucosa on colonoscopy. The diagnosis is made histologically by the presence of increased intraepithelial lymphocytes and mixed inflammatory cells in the lamina propria and a pathognomonic appearance of a thickened subepithelial collagen band.<sup>3</sup> This deposition of collagen distinguishes collagenous colitis from lymphocytic colitis (the other major subtype of microscopic colitis), although some researchers have suggested that the 2 entities may be part of the same spectrum of disease.<sup>4</sup>

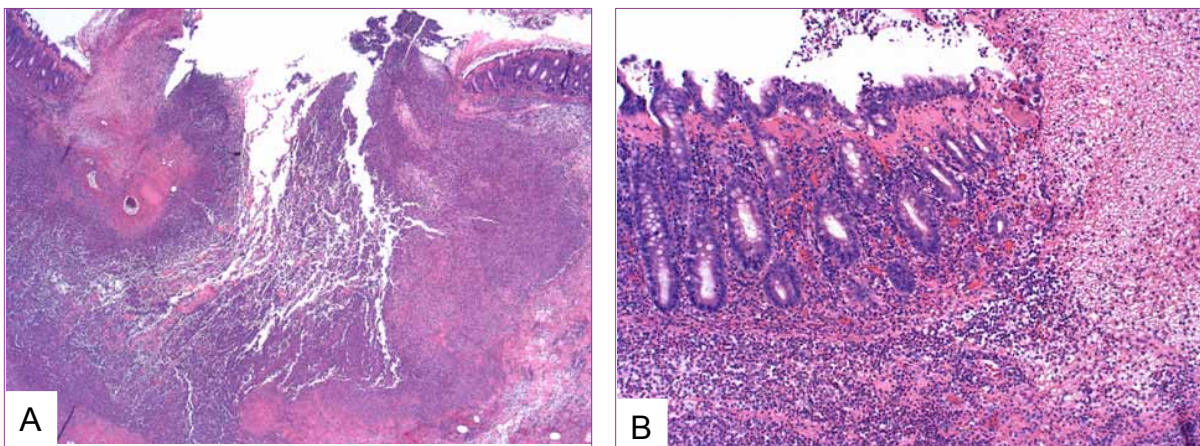
Microscopic colitis most commonly affects women in their fifth and sixth decades of life.<sup>3-5</sup> Several medications have been implicated as contributing factors, notably aspirin and other NSAIDs, histamine 2 receptor blockers, proton pump inhibitors, and certain selective serotonin reuptake inhibitors.<sup>6</sup> Autoimmune conditions, including rheumatoid arthritis, thyroid disorders, and celiac disease, are associated with microscopic colitis.<sup>4</sup> Family history and cigarette smoking also may be risk factors, and postinfectious and paraneoplastic cases have been described.<sup>3,4</sup>

The natural history of disease is typically benign, with intermittent periods of nonbloody, watery diarrhea that can resolve spontaneously, although some patients can have persistent symptoms.<sup>3-5,7</sup> Symptoms may mimic irritable bowel syndrome, and a recent retrospective study suggested that microscopic colitis may be an underdiagnosed cause of chronic diarrhea.<sup>5</sup>

There are several treatment options, including discontinuation of potential triggering medications (noted above) or use of antidiarrheal medications, bismuth subsalicylate, mesalamine, or budesonide.<sup>3,4</sup> A recent meta-analysis demonstrated the efficacy of budesonide



**Figure 1.** Trichrome stains of the colonic mucosa. **A:** A markedly thickened collagen plate, intact crypts, and partial dehiscence of the surface epithelium are shown (200× magnification). **B:** Vascularization and lymphoplasmacytic infiltration of the thickened collagen plate, reparative hyperplasia of the surface epithelium, and intraepithelial lymphocytes (arrows) are shown (400× magnification).



**Figure 2.** Hematoxylin and eosin stains of the colonic mucosa. **A:** The site of perforation within the bowel wall is filled with a neutrophilic infiltrate (40× magnification). **B:** The mucosa shows the histologic features of collagenous colitis adjacent to the perforation site (100× magnification).

in inducing clinical and histologic remission of microscopic colitis.<sup>8</sup> Refractory disease can be treated with immunosuppressive drugs and, very rarely, surgery.<sup>4,9</sup>

Although uncommon, serious complications involving the integrity of the bowel wall have been reported in patients with collagenous colitis. Endoscopically apparent mucosal defects, including longitudinal tears and deeper “fractures,” have been described.<sup>10-13</sup> Colonic perforation and peritonitis following barium enema or colonoscopy have been reported in several small case series.<sup>7,10-13</sup> There are 2 previously reported cases of spontaneous colonic perforation in patients with collagenous colitis.<sup>14,15</sup>

The present case illustrates spontaneous perforation of the colon, a very rare complication of collagenous colitis. This is only the third such case reported in the literature. The patient did not have any other apparent risk factors for perforation, and the only findings at the time of laparotomy

and on pathology were those consistent with collagenous colitis. Prior to the development of an acute abdomen necessitating partial colectomy, the patient had had the typical symptoms of microscopic colitis for 2 months.

Several recent case series have described colonic perforations and mucosal tears in patients with collagenous colitis undergoing colonoscopy or barium enema.<sup>7,10-16</sup> Although descriptions of colonoscopic findings were not available in all cases and were normal in other cases, many of the reported perforations were associated with linear mucosal tears.<sup>7,11-13,16</sup> Although these mucosal abnormalities were observed in all parts of the colon, a disproportionate number occurred in the right colon, which is consistent with the available evidence and suggests that collagenous colitis has a right-sided predilection.<sup>11,12</sup> Interestingly, in the 2 previously reported cases of spontaneous perforation, as well as in the present case, perforation occurred in the left colon (Table).

**Table.** Demographics of Reported Cases of Spontaneous Bowel Perforation in Patients with Collagenous Colitis

Case	Patient age (yrs)	Comorbidities and risk factors	Medications	Location of perforation	Surgical outcome
Freeman HJ, et al <sup>14</sup>	37	None	None	Sigmoid colon	Exploratory laparotomy, no resection
Bohr J, et al <sup>15</sup>	56	Depression, tobacco use	Clomipramine, herbal colon cleanser	Splenic flexure/ descending colon	Segmental resection and anastomosis
Present case	67	None	Aspirin	Splenic flexure	Partial colectomy and transverse colostomy with subsequent anastomosis

These recent descriptions of endoscopically visible mucosal defects in patients with collagenous colitis are of considerable interest; when observed, they raise the possibility of this diagnosis, which previously could only be made microscopically.

A recent review of this subject strove to categorize endoscopic findings from the small case series that make up the current body of knowledge and reported 4 patterns of mucosal abnormalities: pseudomembranes; an indistinct or crowded appearance of vasculature; mucosal abnormalities, such as red spots or nodularity; and a continuum of characteristic linear mucosal tears, including a “cat scratch” pattern and thicker scarred “fractures.”<sup>10</sup> The authors of the review noted that such findings were only visible in a small percentage of cases of collagenous colitis and may not always be distinguishable from similar findings in other conditions<sup>10</sup>; however, their presence should alert endoscopists to the increased risk of complications, including perforation.<sup>10,11</sup>

## Summary

Although rare, the risk of mucosal tearing and colonic perforation in patients with collagenous colitis represents a severe and life-threatening extreme of a continuum of illness typically thought of as benign. The present case serves to illustrate the importance of considering the diagnosis of collagenous colitis in patients with chronic non-bloody diarrhea, especially in the high-risk demographic of middle-aged and elderly women.

## References

- Freeman HJ, Weinstein WM, Shnitka TK, Wensel RH, Sartor VE. Watery diarrhea syndrome associated with a lesion of the colonic basement membrane (CD)-lamina propria (LP) interface. *Ann R Coll Phys Surg Can.* 1976;9:45.
- Lindstrom CG. Collagenous colitis with watery diarrhea—a new entity? *Pathol Eur.* 1976;11:87-89.
- Freeman HJ. Collagenous mucosal inflammatory diseases of the gastrointestinal tract. *Gastroenterology.* 2005;129:338-350.
- Pardi DS, Kelly CP. Microscopic colitis. *Gastroenterology.* 2011;140:1155-1165.
- Mohamed N, Marais M, Bezuidenhout J. Microscopic colitis as a missed cause of chronic diarrhea. *World J Gastroenterol.* 2011;17:1996-2002.
- Beaugerie L, Pardi DS. Review article: drug-induced microscopic colitis—proposal for a scoring system and review of the literature. *Aliment Pharmacol Ther.* 2005;22:277-284.
- Freeman HJ. Complications of collagenous colitis. *World J Gastroenterol.* 2008;14:1643-1645.
- Chande N, Macdonald JK, McDonald JW. Interventions for treating microscopic colitis: a Cochrane Inflammatory Bowel Disease and Functional Bowel Disorders Review Group systematic review of randomized trials. *Am J Gastroenterol.* 2009;104:235-241.
- Williams RA, Gelfand DV. Total proctocolectomy and ileal pouch anal anastomosis to successfully treat a patient with collagenous colitis. *Am J Gastroenterol.* 2000;95:2147.
- Koulaouzidis A, Saeed AA. Distinct colonoscopy findings of microscopic colitis: not so microscopic after all? *World J Gastroenterol.* 2011;17:4157-4165.
- Hussain Z, Kelly S, Clarke A, et al. Colonic perforation in collagenous colitis: a systematic review of a rare complication and guidance on management. *Surg Endosc.* 2010;24:2930-2934.
- Allende DS, Taylor SL, Bronner MP. Colonic perforation as a complication of collagenous colitis in a series of 12 patients. *Am J Gastroenterol.* 2008;103:2598-2604.
- Sherman A, Ackert JJ, Rajapaksa R, West AB, Oweity T. Fractured colon: an endoscopically distinctive lesion associated with colonic perforation following colonoscopy in patients with collagenous colitis. *J Clin Gastroenterol.* 2004;38:341-345.
- Freeman HJ, James D, Mahoney C. Spontaneous peritonitis from perforation of the colon in collagenous colitis. *Can J Gastroenterol.* 2001;15:265-267.
- Bohr J, Larsson LG, Eriksson S, et al. Colonic perforation in collagenous colitis: an unusual complication. *Eur J Gastroenterol Hepatol.* 2005;17:121-124.
- Wickbom A, Lindqvist M, Bohr J, et al. Colonic mucosal tears in collagenous colitis. *Scand J Gastroenterol.* 2006;41:726-729.

# Review

## Acute Surgical Abdomen in Collagenous Colitis

Hugh J. Freeman, MD

*Department of Medicine (Gastroenterology)  
University of British Columbia  
Vancouver, British Columbia, Canada*

The most striking aspect of the case report by Bennett and colleagues is the clear pathologic demonstration of an entirely benign colonic perforation in the mucosa that showed typical histopathologic features of collagenous colitis.<sup>1</sup> The features of collagenous colitis have been reviewed elsewhere.<sup>2</sup>

Our understanding of the long-term natural history of collagenous colitis has grown over the nearly 40 years since the disorder was first described in January 1976 by both Canadian and Swedish researchers in separate studies.<sup>3,4</sup> In the Canadian report by Freeman and colleagues,<sup>3</sup> a distinctive pathologic mucosal lesion was first noted in 2 women who were experiencing watery diarrhea.<sup>3</sup> The presence of collagen was suspected on routine light microscopic evaluation and special histochemical studies. Electron microscopic studies of the colonic mucosal biopsies confirmed the ultrastructural presence of collagen fibers.

In the Swedish case report by Lindstrom and colleagues, which involved a woman who was experiencing watery diarrhea, light microscopic findings of the presence of collagen also were independently confirmed.<sup>4</sup> At a much later date, ultrastructural changes similar to those seen in the Canadian case were independently confirmed.<sup>5</sup>

Large clinical survey series, mainly from Scandinavian centers, subsequently demonstrated that middle-aged and elderly women were the population most at risk for collagenous colitis.<sup>6,7</sup> The disorder usually has a benign clinical course, at least during an evaluation period of about 10 years.<sup>8</sup> In most cases, persistent diarrhea develops; otherwise, intermittent periods of recurrent diarrhea develop. Spontaneous resolution has been recorded, making it difficult to evaluate responsiveness to different forms of treatment. Because the characteristic subepithelial collagen deposits may be patchy and variable in depth or they may be focal rather than diffuse and continuous in

some parts of the colonic mucosa, a histologic endpoint regarding subepithelial collagen deposits has been difficult to estimate when designing clinical trials. Treatment has been focused largely on symptom resolution with high-fiber diets, nonspecific antidiarrheal agents, and anti-inflammatory agents, particularly the 5-aminosalicylate class of medications. Corticosteroids, such as delayed-release budesonide, also may provide symptomatic relief.<sup>2</sup> Other agents, including immunosuppressive agents and biologics, have been empirically used.

In recent years, the relationship between collagenous colitis and other disorders has been explored. Other immune-mediated diseases have been closely linked to collagenous colitis, including arthritis, spondylitis, thyroiditis, and some dermatologic disorders, including pyoderma gangrenosum.<sup>2</sup> Other gastrointestinal disorders also may develop. Celiac disease, for example, has been detected in about 20% of patients.<sup>9</sup> Moreover, in some cases of collagenous colitis, inflammatory mucosal disease marked by collagen deposits may be detected elsewhere in the gastrointestinal tract, including the stomach and small bowel, suggesting that collagenous colitis may be a very heterogeneous disorder.<sup>10</sup> Interestingly, it is uncommon to see malignant colonic complications in the clinical course of collagenous colitis,<sup>11</sup> but the associated malignancies have included adenocarcinoma, lymphoma, and neuroendocrine neoplastic disease, specifically carcinoids.<sup>12,13</sup>

Although collagenous colitis has a benign and sometimes relapsing and remitting course in most patients, some serious complications can occur. Rarely, a severe and protracted course may be seen, and, in at least one report, a fatal outcome was attributed directly to the colitis.<sup>14</sup> In some patients, a prominent histologic feature of surface epithelial cell sloughing may be detected, providing visual evidence of enhanced mucosal permeability and protein-losing enteropathy.<sup>15</sup> Colonic ulceration may occur and is possibly related to concomitant use of medications, particularly nonsteroidal anti-inflammatory drugs.<sup>16</sup> Rarely, collagenous colitis may progress to inflammatory bowel disease. In one report of collagenous colitis that progressed to severe ulcerative colitis and necessitated colectomy, complete disappearance of preexistent collagen deposits in the resected colon was noted.<sup>17</sup>

Other serious colonic complications have been recorded. As in the report by Bennett and colleagues,<sup>1</sup> spontaneous peritonitis with colonic perforation has been previously noted.<sup>18</sup> Peritonitis with colonic perforation is perhaps related to colonic wall compromise that is associated with submucosal collagen deposition. Submucosal dissection has been described.<sup>19</sup> In some cases, changes related to investigative procedures, particularly endoscopic instrumentation possibly due to air insufflation and barotraumas, have been described, and the term "colonic fracturing" has

*Address correspondence to:*

Dr. Hugh J. Freeman, UBC Hospital, 2211 Wesbrook Mall, Vancouver, British Columbia, Canada V6T 1W5; Tel: 604-822-7216; Fax: 604-822-7236; E-mail: hugfree@shaw.ca

emerged.<sup>20</sup> Indeed, endoscopists noting these changes during colonoscopic evaluation might be advised to maintain close observation of patients following colonoscopy.

In summary, a variety of clinical presentations for collagenous colitis have become increasingly recognized. Although chronic or recurrent nonbloody diarrhea is most common, collagenous colitis may initially present with or be complicated by serious findings, including an acute surgical abdomen, which requires urgent surgical treatment. In this situation, an acute colonic perforation deserves special diagnostic attention, especially if the perforation developed following colonoscopic evaluation or in a patient with known collagenous colitis.

## References

- Bennett M, Tompkins H, Seymour B, O'Brien M, Farraye FA. Spontaneous colonic perforation in a patient with collagenous colitis. *Gastroenterol Hepatol (N Y)*. 2013;9:262-264.
- Freeman HJ. Collagenous mucosal inflammatory diseases of the gastrointestinal tract. *Gastroenterology*. 2005;129:338-350.
- Freeman HJ, Weinstein WM, Shnitka TA, Wensel RH, Sartor VE. Watery diarrhea syndrome associated with a lesion of the colonic basement membrane-lamina propria interface. *Ann R Coll Phys Surg Can*. 1976;9:45.
- Lindstrom CG. Collagenous colitis with watery diarrhea—a new entity? *Pathol Eur*. 1976;11:87-89.
- Widgren S, Jlidi R, Cox JN. Collagenous colitis: histologic, morphometric, immunohistochemical and ultrastructural studies. Report of 21 cases. *Virchows Arch*. 1988;413:287-296.
- Olesen M, Eriksson S, Bohr J, Jarnerot G, Tysk C. Microscopic colitis: a common diarrheal disease. An epidemiological study in Orebro, Sweden 1993-1996. *Gut*. 2004;53:346-350.
- Agnarsdottir M, Gunnlaugsson O, Orvar KB, et al. Collagenous and lymphocytic colitis in Iceland. *Dig Dis Sci*. 2002;47:1122-1128.
- Madisch A, Miehke S, Lindner M, Bethke B, Stolte M. Clinical course of collagenous colitis over a period of 10 years. *Z Gastroenterol*. 2006;44:971-974.
- Freeman HJ. Collagenous colitis as the presenting feature of biopsy-defined celiac disease. *J Clin Gastroenterol*. 2004;38:664-668.
- Pulimood AB, Ramakrishna BS, Mathan MM. Collagenous gastritis and collagenous colitis: a report with sequential histological and ultrastructural findings. *Gut*. 1999;44:881-885.
- Chan JL, Tersmette AC, Offerhaus GJ, Gruber SB, Bayless TM, Giardiello FM. Cancer risk in collagenous colitis. *Inflamm Bowel Dis*. 1999;5:40-43.
- Freeman HJ. Lymphoproliferative disorders in collagenous colitis. *Inflamm Bowel Dis*. 2005;11:781-782.
- Nussinson E, Samara M, Vigder L, Shafer I, Tzur N. Concurrent collagenous colitis and multiple ileal carcinoids. *Dig Dis Sci*. 1988;33:1040-1044.
- Widgren S, MacGee W. Collagenous colitis with protracted course and fatal evolution. Report of a case. *Pathol Res Pract*. 1990;87:703-709.
- Stark ME, Batts KP, Alexander GL. Protein-losing enteropathy with collagenous colitis. *Am J Gastroenterol*. 1992;87:780-783.
- Kakar S, Pardi DS, Burgart LJ. Colonic ulcers accompanying collagenous colitis: implication of nonsteroidal anti-inflammatory drugs. *Am J Gastroenterol*. 2003;98:1834-1837.
- Freeman HJ, Berean KW, Nimmo M. Evolution of collagenous colitis into severe and extensive ulcerative colitis. *Can J Gastroenterol*. 2007;21:315-318.
- Freeman HJ, James D, Mahoney CJ. Spontaneous peritonitis from perforation of the colon in collagenous colitis. *Can J Gastroenterol*. 2001;15:265-267.
- Mitchell JD, Teague R, Bolton R, Lowes J. Submucosal "dissection" in collagenous colitis. *Gut*. 2004;53:470.
- Sherman A, Ackert J, Rajapaksa R, West AB, Owelty T. Fractured colon: an endoscopically distinctive lesion associated with colonic perforation following colonoscopy in patients with collagenous colitis. *J Clin Gastroenterol*. 2004;38:341-345.